DISCLOSURE

- SPEAKER BUREAU FOR GENERAL ELECTRIC
- CONSUTANT FOR GENERAL ELECTRIC
- CONSULTANT FOR HEARTFLOW
- SPEAKER BUREAU FOR MEDTRONIC
- SPEAKER BUREAU FOR BAYER

BACKGROUND: left ventricle mass, volume and function evaluation

Clinical Change	Echo (SD/N)	MRI (SD/N)	Reduction in sample size (%)
EDV, 10 ml	23.8/121	7.4/12	90
ESV, 10 ml	15.8/53	6.5/10	81
EF, 3%	6.6/102	2.5/15	85
Mass, 10 gr	36.4/273	6.4/9	97

Bellinger NG J Cardiovasc Magn Reson 2000

1. Left ventricle mass

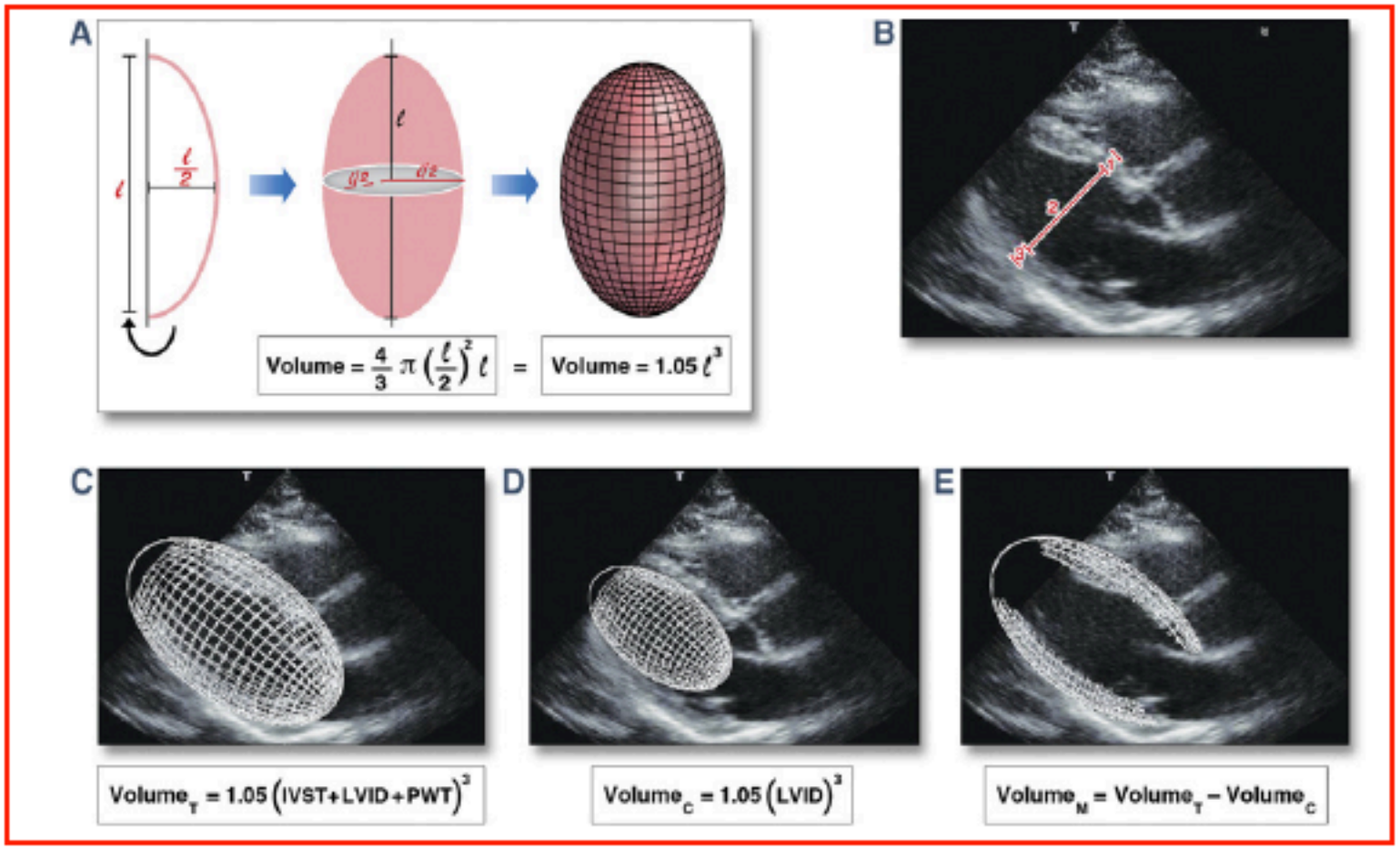

F $LVM + 0.8 \times \left[1.05\,(IVST+LVID+PWT)^3 - (LVID)^3\right] + 0.8\ g$

Centro Cardiologico Monzino

Armstrong A JACC CI 2012

1. Left ventricle mass and volume

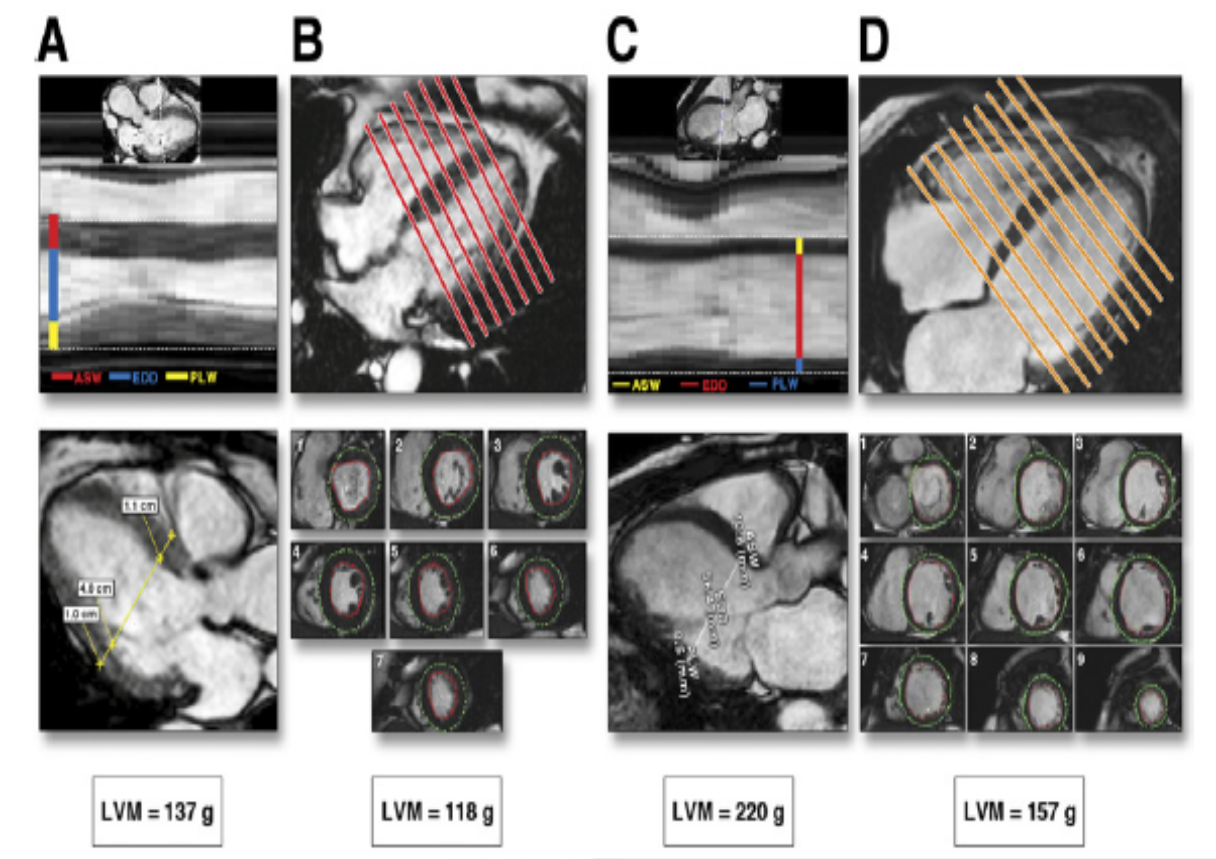

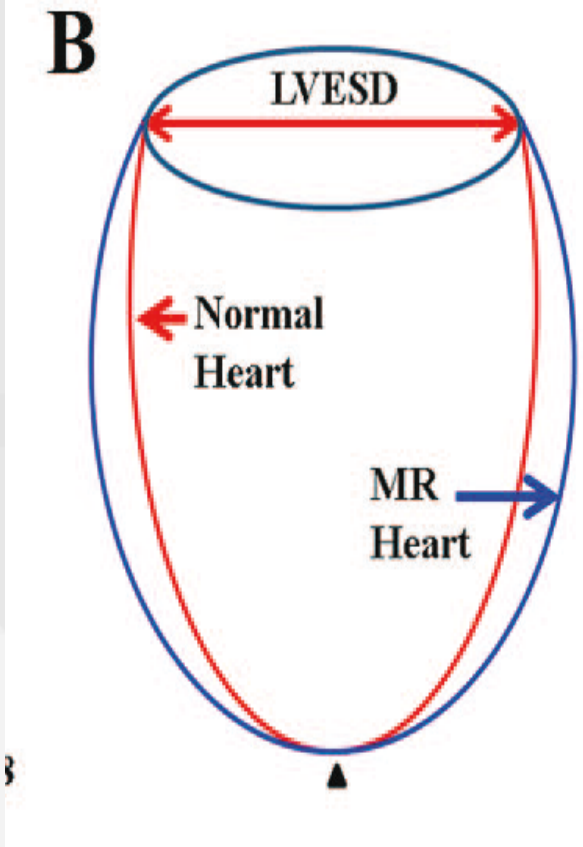

Case 1 has preserved cardiac geometry, but case 2 shows left ventricular remodeling. The usual assessment of LVM by cardiac magnetic resonance (CMR) does not require cardiac geometry assumptions, as opposed to linear measurements used in echocardiography. (Courtesy of Dr. Gustavo Volpe.) (A and C) CMR-derived images representing usual echocardiography views for linear measurements assessing LVM. The anterior septal wall (ASW) corresponds to the interventricular septal thickness; the end-diastolic dimension (EDD) corresponds to the left ventricular internal dimension; and the posterior lateral wall (PLW) corresponds to the posterior wall thickness. At the bottom, the ASE-recommended formula was used to calculate LVM (see Fig. 1 for a full description). (B and D) Usual CMR assessment for LVM, using contiguous short-axis slices covering the entire left ventricle from the atrioventricular ring to the apex (1 to 9). The estimated LVM is displayed at the bottom.

Armstrong A JACC CI 2012

3. Right ventricle volume and function

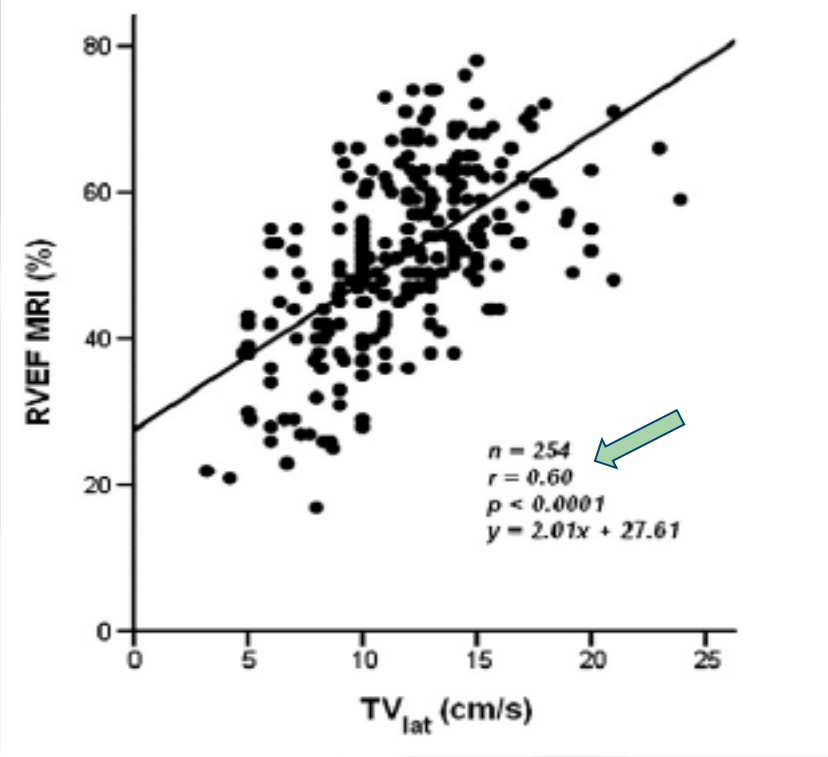

Correlation between lateral tricuspid annular systolic motion velocity (Tvlat, horizontal axis) and right ventricular ejection fraction as obtained by cardiac magnetic resonance (RVEF MRI, vertical axis).

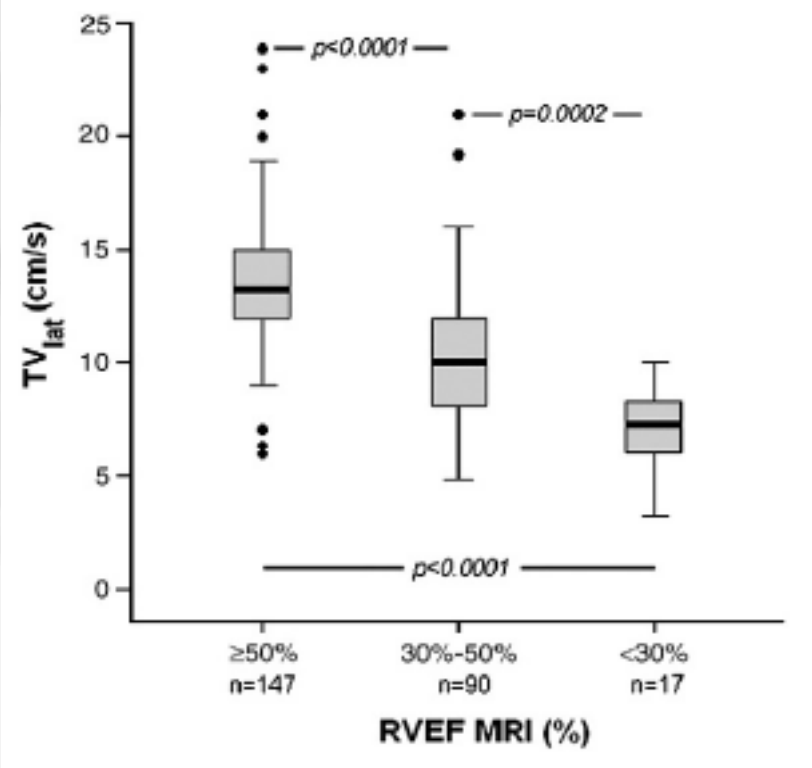

Lateral tricuspid annular systolic motion velocities (TVlat, vertical axis) in 3 groups of right ventricular ejection fraction as obtained by cardiac magnetic resonance (horizontal axis). Bar graphs indicate mean values and 75% confidence intervals, error bars show 90% confidence limits, and beyond those, individual values are depicted.

Wahl A IJC 2011

Centro Cardiologico
Monzino

3. Right ventricle volume and function

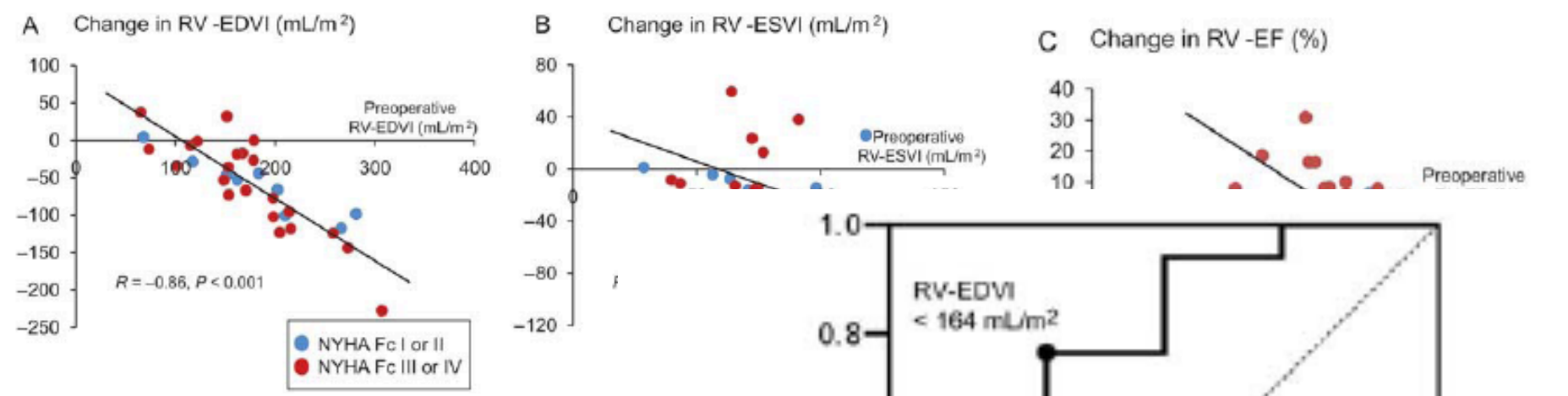

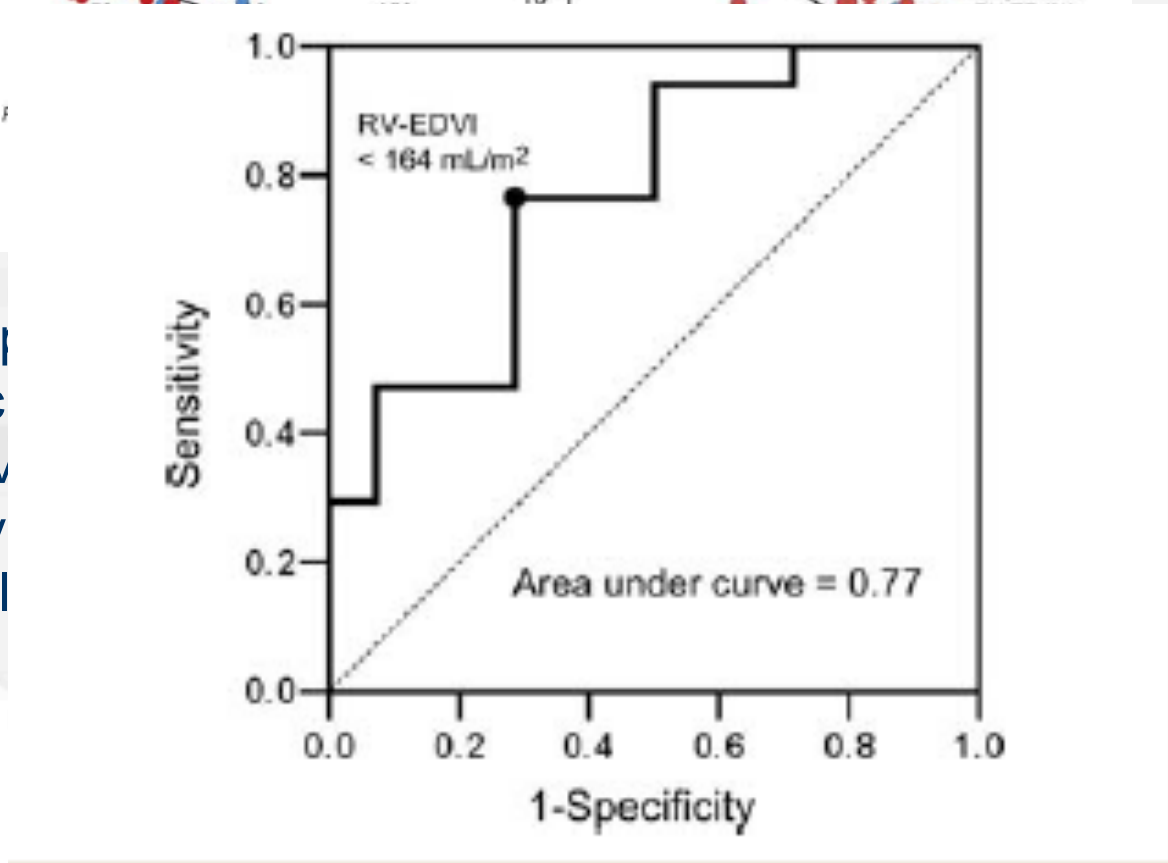

Associations between pre-op
EDVI) (A), RV end-systolic
fraction (RV-EF) (C), or RV
(eRV-EF) (D) and respectiv
Note the absence of threshol
RV systolic function occurs.

Centro Cardiologico
Monzino

Kim HK EHJ 2010

3. Right ventricle volume and function

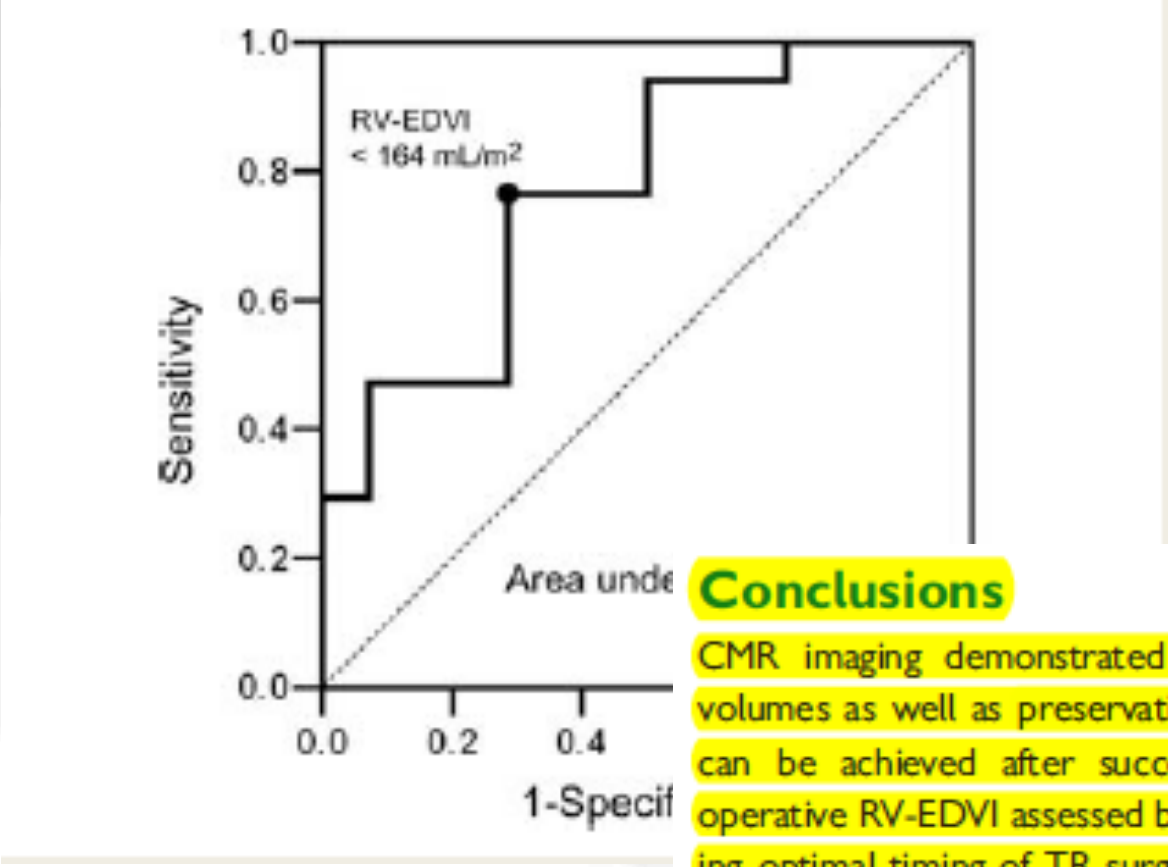

Receiver-operating characteristic curve is depicted for postoperative normal RV-EF in relation to pre-operative RV-EDVI determined by cardiac magnetic resonance imaging. With a cut-off value of 164 mL/m2, sensitivity and specificity of postoperative normal RV-EF were 77 and 72%, respectively.

Conclusions

CMR imaging demonstrated that remarkable reduction in RV volumes as well as preservation of RV-EF within a normal range can be achieved after successful corrective TR surgery. Pre-operative RV-EDVI assessed by CMR has a potential for determining optimal timing of TR surgery, although requiring confirmation in a large-scale study. In addition, successful TR surgery led to a significant rise in LV preload and CI, which may significantly

4. Tissue characterization: late gadolinium enhancement

Early after the first pass of Gd, a significant fraction of the injected Gd enters the interstitial space. Several minutes after intravenous administration of Gd, the larger volume of distribution available in necrotic or fibrotic myocardium results in a higher concentration of contrast agent than what is present in viable myocardium. This is typically referred to as "delayed (hyper)enhancement" or "late gadolinium enhancement" (LGE).

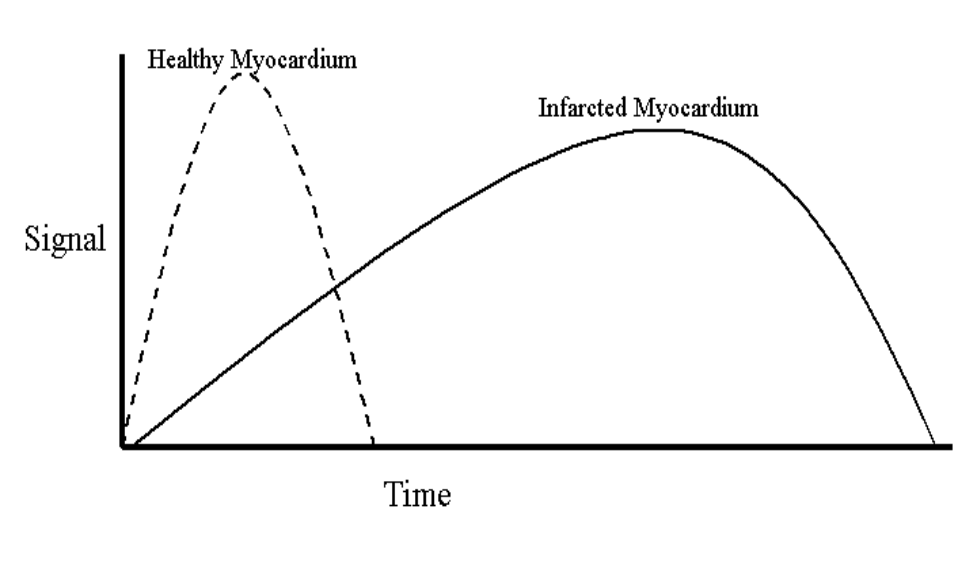

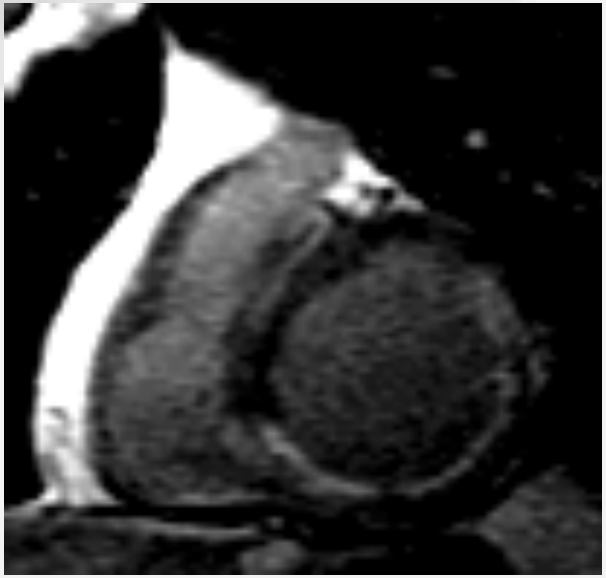

4. Tissue characterization: T1 mapping

- Intended for quantitative pixel-wise T_1 mapping

<u>Potential Benefits:</u>

- Detection of diffuse cardiac fibrosis
- Improved tissue characterization

- GE exclusive **SMART$_1$Map: S**aturation **M**ethod using **A**daptive **R**ecovery **T**imes for T_1 **Map**ping[1,2]
- Accurate single-point approach measures *true* T_1 rather than *apparent* T_1 (T_1*), unlike other approaches
- Sampling of delay times across multiple heart-beats yields T1 measurement precision
- Robust method insensitive to <u>all</u> imaging parameters, e.g. heart rate, arrhythmia, readout window, flip angle
- T1 map generated online automatically

[1] Slavin et al. SCMR 2013 #P3; [2] Stainsby et al. SCMR 2013 #P13

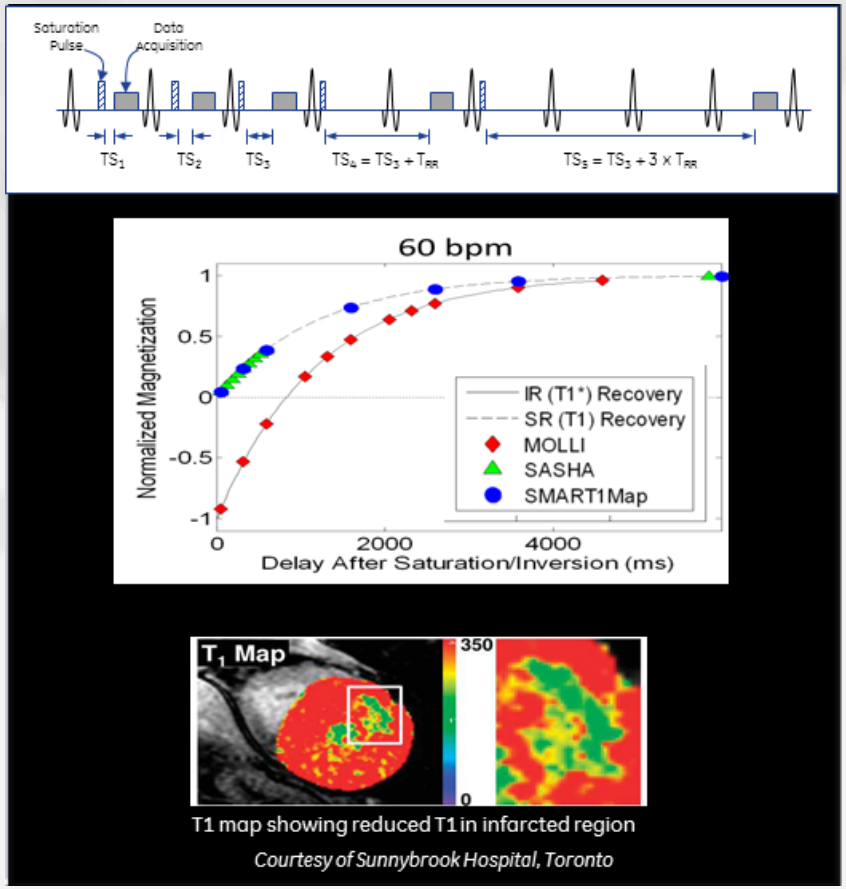

T1 map showing reduced T1 in infarcted region

Courtesy of Sunnybrook Hospital, Toronto

Technology in development that represents ongoing research and development efforts. These technologies are not products and may never become products. Not for sale. Not CE marked. Not cleared, approved or authorized by the U.S. FDA or other national regulatory authorities for commercial availability.

DCM: clinical classification

- Currently a morphological classification and functional, is still the most clinically useful, since it allows to perform a prognostic evaluation and outline a therapeutic strategy

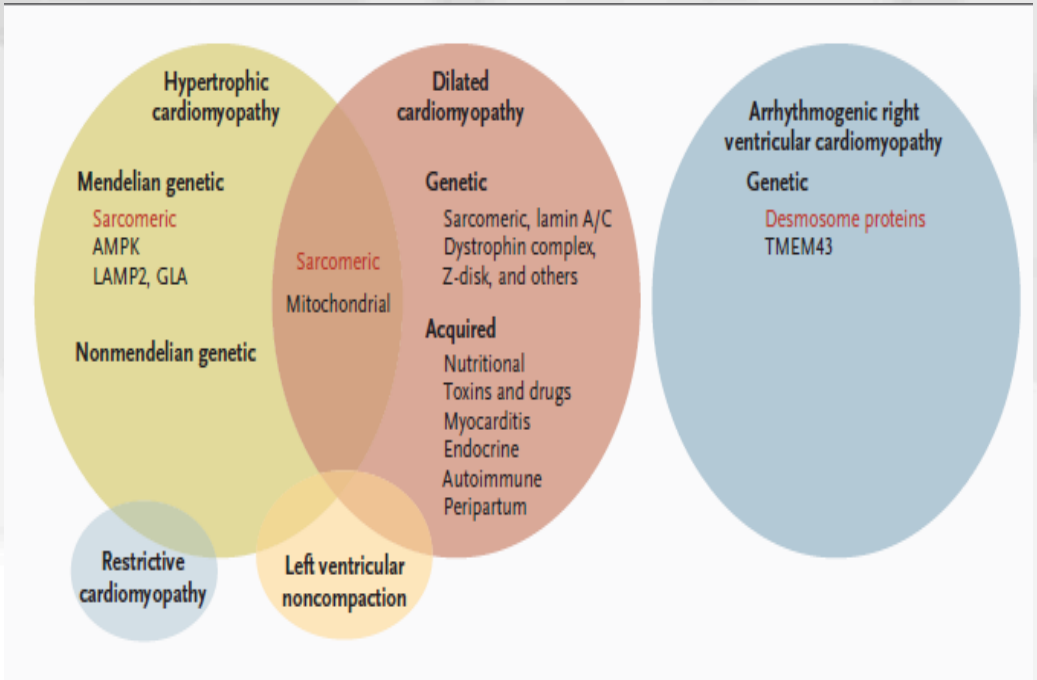

Special article

Clinical indications for cardiovascular magnetic resonance (CMR): Consensus Panel report☆

Dudley J. Pennell*, Udo P. Sechtem, Charles B. Higgins, Warren J. Manning, Gerald M. Pohost, Frank E. Rademakers, Albert C. van Rossum, Leslee J. Shaw, E. Kent Yucel

Cardiovascular Magnetic Resonance Unit, Royal Brompton Hospital, Sydney Street, London SW3 6NP, UK

Table 4 Indications for CMR in patients with pericardial disease, cardiac tumours, cardiomyopathies, and cardiac transplants

Indication	Class
5. Hypertrophic cardiomyopathy	
Apical	I
Non-apical	II
6. Dilated cardiomyopathy	
Differentiation from dysfunction related to coronary artery disease	I
7. Arrhythmogenic right ventricular cardiomyopathy (dysplasia)	I
8. Restrictive cardiomyopathy	II
9. Siderotic cardiomyopathy (in particular thalassemia)	I
10. Non compaction	II

Centro Cardiologico Monzino

N Engl J Med 2011;364:1643-56.

① Hypertrophic cardiomyopathy
Differential diagnosis vs physiological hypertrophy

	Pathological left-ventricular hypertrophy (hypertrophic cardiomyopathy)	Physiological left-ventricular hypertrophy (athlete's heart)
Focal pattern of left-ventricular hypertrophy	+	0
Left-ventricular cavity <45 mm	+	0
Left-ventricular cavity >55 mm	0	+
Left atrium enlargement	+	0
Bizarre ECG patterns	+	+
Abnormal left-ventricular filling	+	0
Family history of hypertrophic cardiomyopathy	+	0
Decreased thickness with deconditioning	0	+
VO_2 increase >110%	0	+
Late gadolinium enhancement	+	0
Pathogenic sarcomere mutation	+	0

ECG=electrocardiogram. VO_2=peak oxygen consumption. +=present. 0=absent. Modified from reference 65, with permission of the American Heart Association.

Table: **Distinguishing hypertrophic cardiomyopathy from athlete's heart when left-ventricular hypertrophy is within the grey zone of overlap (thickness, 13–15 mm in males and 11–12 mm in females)**

Centro Cardiologico Monzino

Lancet 2013; 381: 242–55

① Hypertrophic cardiomyopathy

Mass as predictor of worse prognosis

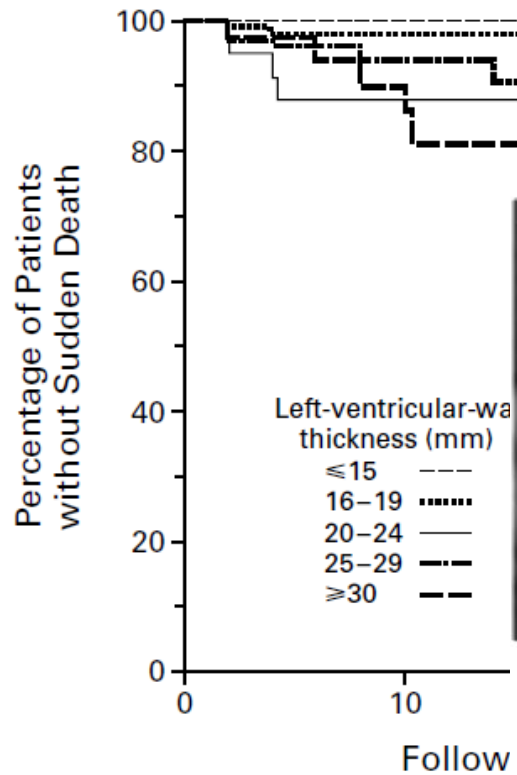

Figure 2. Kaplan–Meier Estimates of
without Sudden Death among the
trophic Cardiomyopathy, According
Ventricular Hypertrophy.

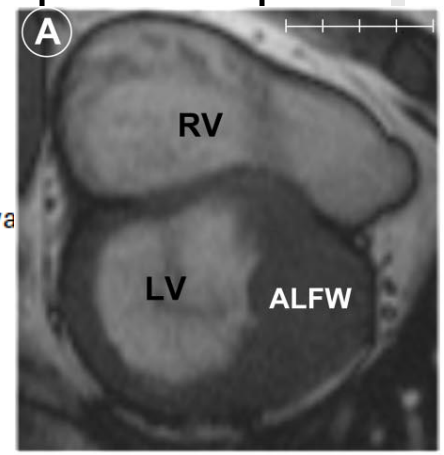

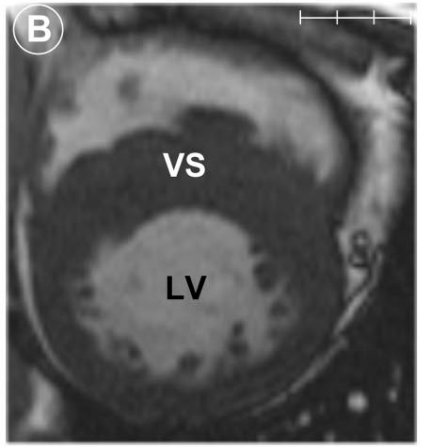

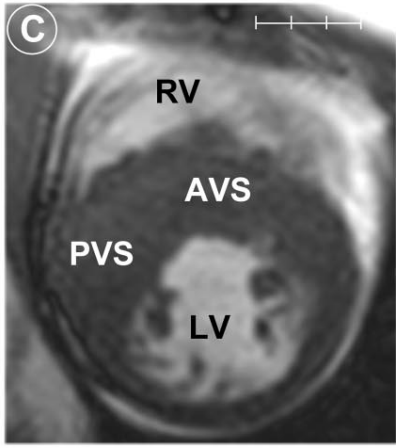

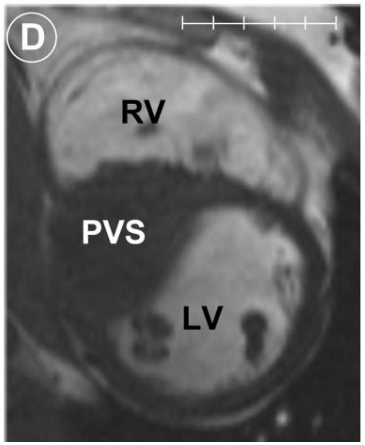

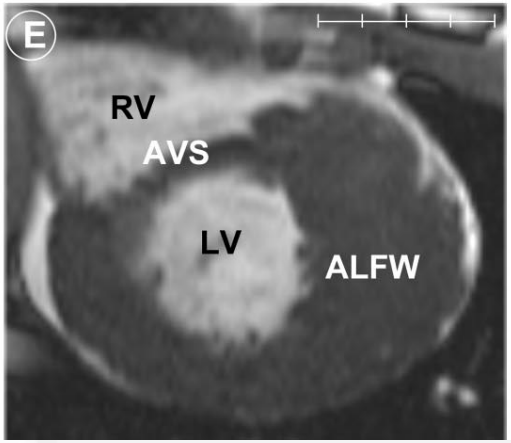

Centro Cardiologico
Monzino

① Hypertrophic cardiomyopathy

LGE as predictor of worse prognosis

Journal of the American College of Cardiology
© 2002 by the American College of Cardiology Foundation
Published by Elsevier Science Inc.

Vol. 40, No. 12, 2002
ISSN 0735-1097/02/$22.00
PII S0735-1097(02)02602-5

Hypertrophic Cardiomyopathy

Myocardial Scarring in Asymptomatic or Mildly Symptomatic Patients With Hypertrophic Cardiomyopathy

Lubna Choudhury, MD, MRCP, Heiko Mahrholdt, MD, Anja Wagner, MD, Kelly M. Choi, MD, Michael D. Elliott, MD, Francis J. Klocke, MD, MACC, Robert O. Bonow, MD, FACC, Robert M. Judd, PHD, Raymond J. Kim, MD, FACC

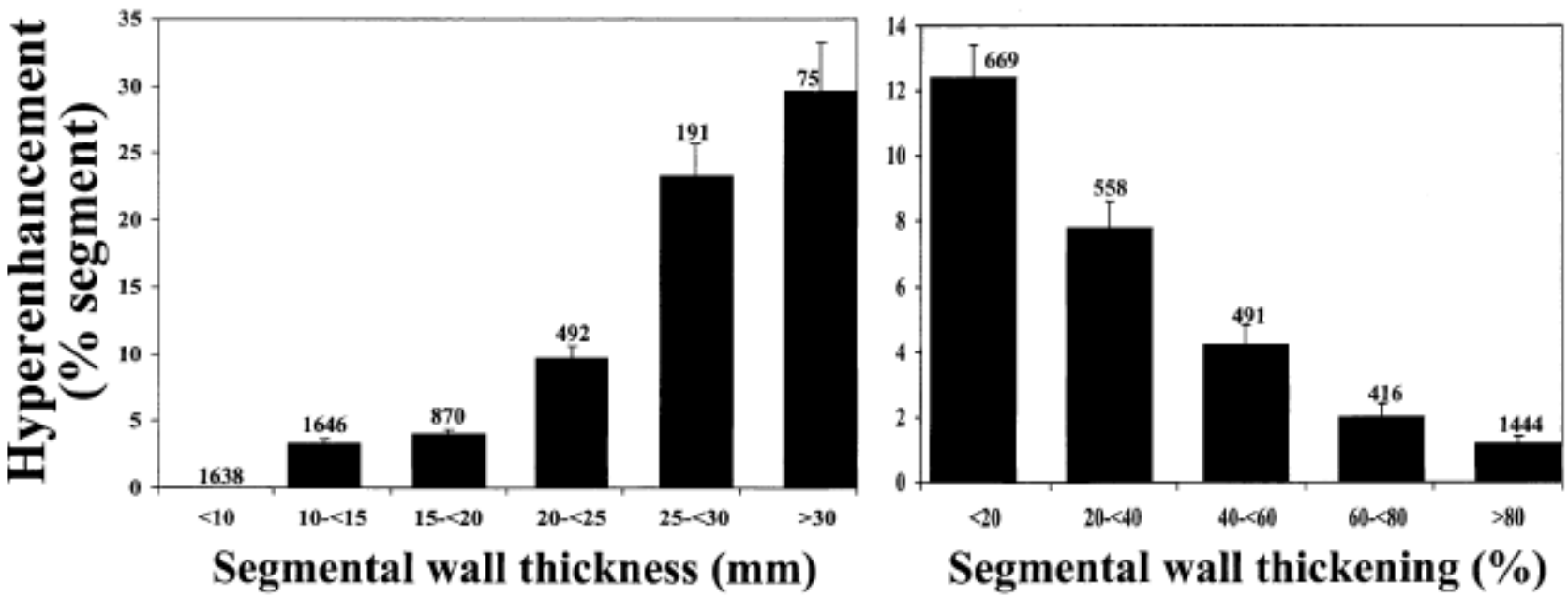

① Hypertrophic cardiomyopathy

LGE as predictor of worse prognosis

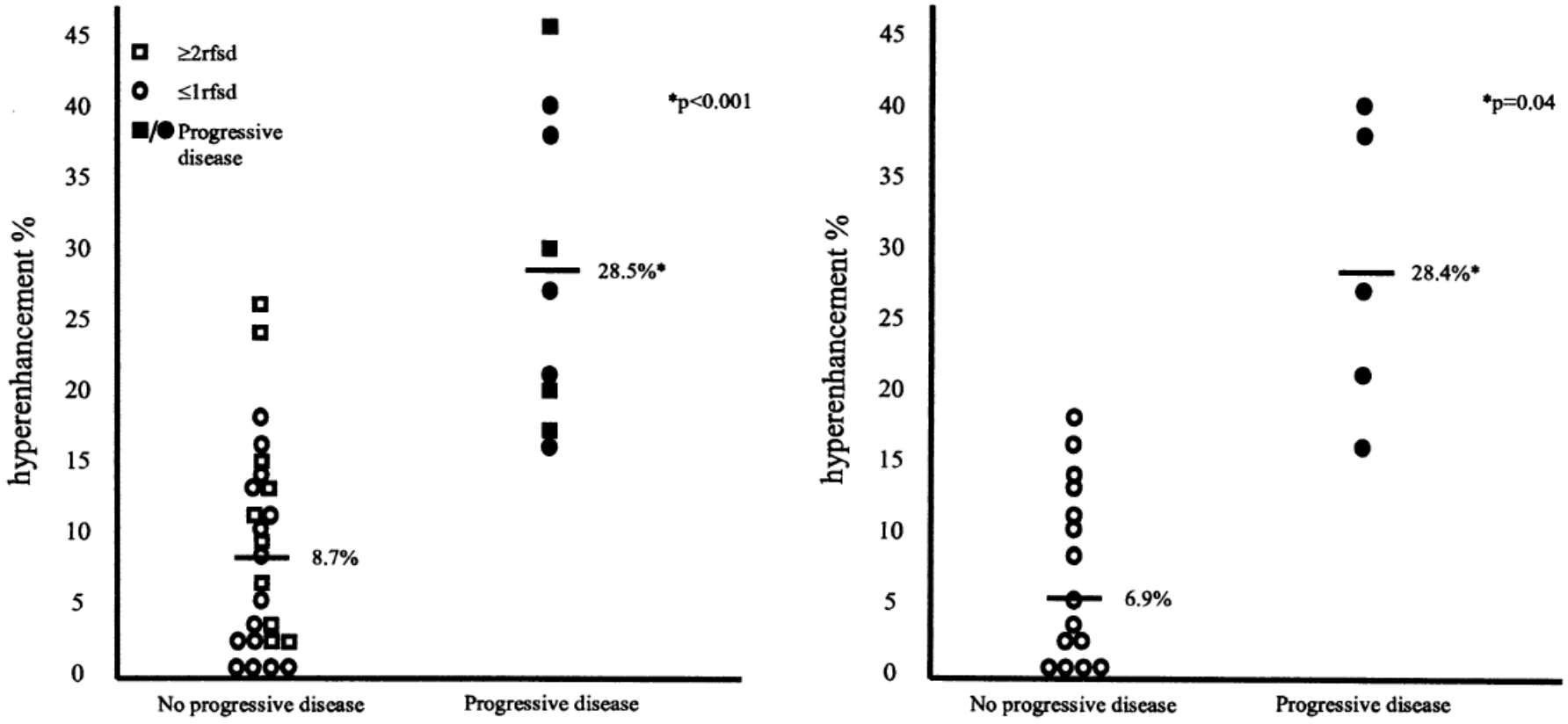

Centro Cardiologico Monzino

Choudhury L JACC 2012

① Hypertrophic cardiomyopathy
LGE as predictor of worse prognosis

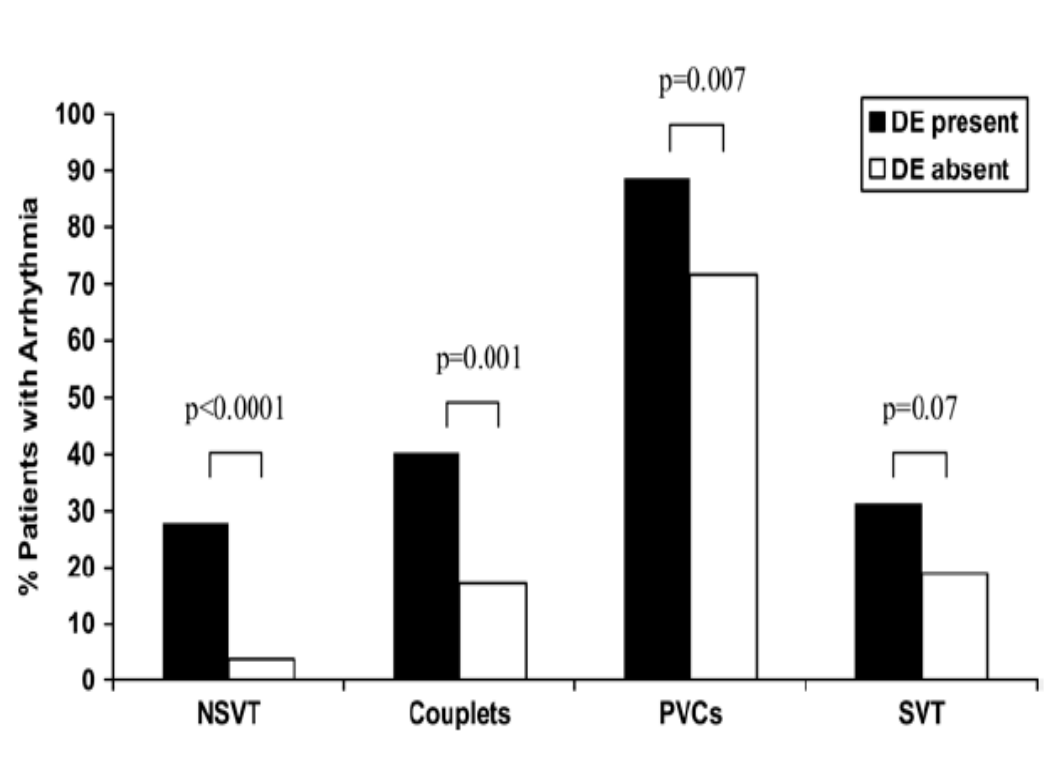

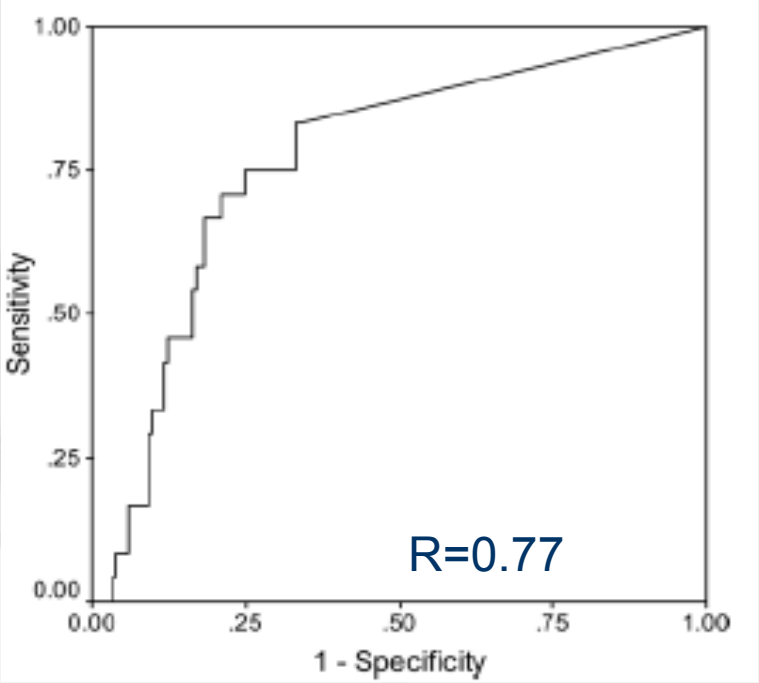

Figure 2 ROC Curve to Assess Ability of DE to Discriminate Patients With and Without NSVT on Holter ECG

In multivariate analysis, after adjustment for age and maximum thickness, the presence of ED was the only independent predictor of NSVT (p 0.0001)

Centro Cardiologico Monzino

Seleuk Adabag A, JACC 2010

① Hypertrophic cardiomyopathy

LGE as predictor of worse prognosis

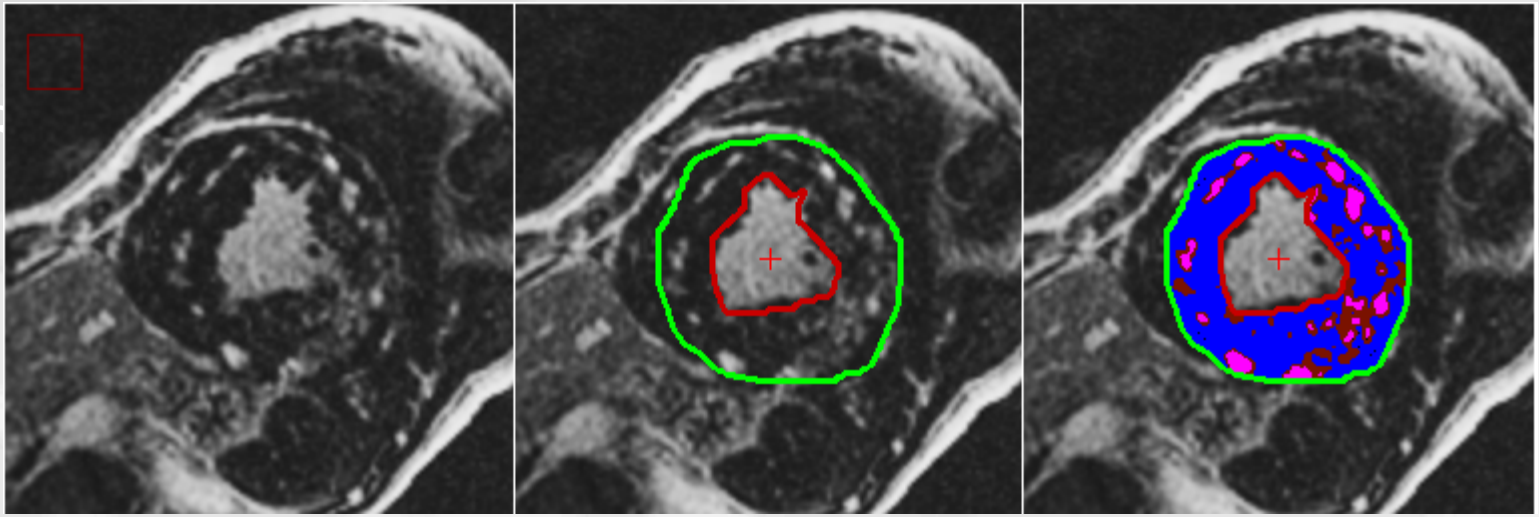

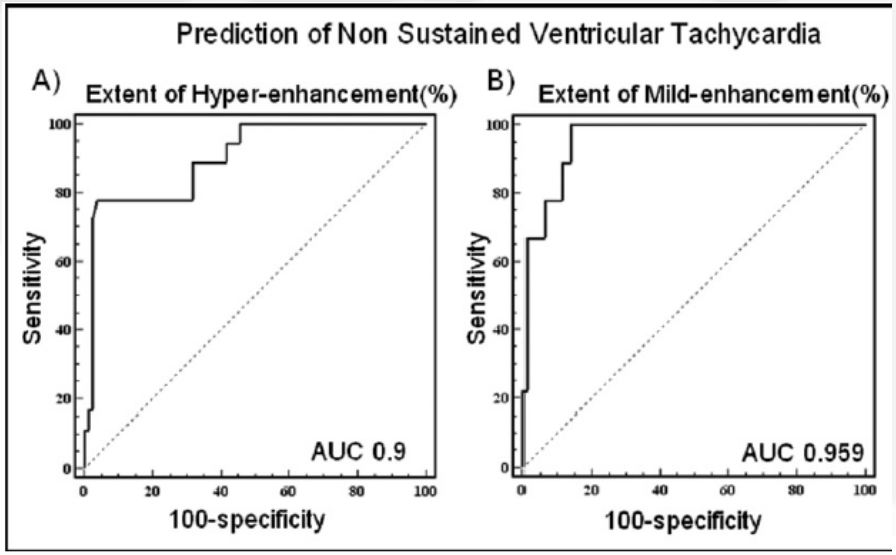

Prediction of Non Sustained Ventricular Tachycardia

-Extent of **Hyper-enhancement**(%); Cut off >2.4

76.5% sensitivity

96.2% specificity

-Extent of **Mild-enhancement**(%); Cut off >4.9

100% sensitivity

81.6% specificity

Centro Cardiologico Monzino

Aquaro GD, Circulation 2010

Aquaro GD, Eur Heart J 2010 in press

① Hypertrophic cardiomyopathy

LGE as predictor of worse prognosis

Myocardial Scar Visualized by Cardiovascular Magnetic Resonance Imaging Predicts Major Adverse Events in Patients With Hypertrophic Cardiomyopathy

Oliver Bruder, MD,* Anja Wagner, MD,† Christoph J. Jensen, MD,* Steffen Schneider, PHD,‡ Peter Ong, MD,§ Eva-Maria Kispert, RN,§ Kai Nassenstein, MD,‖ Thomas Schlosser, MD,‖ Georg V. Sabin, MD,* Udo Sechtem, MD,§ Heiko Mahrholdt, MD§

Table 5 Univariate Analysis: Cardiac Mortality

	No Cardiac Mortality (n = 204)	Cardiac Mortality (n = 16)	p Value	OR (95% CI)
Age, yrs	57.0 (46.0–68.0)	61.5 (57.0–73.0)	<0.05	1.04 (1.00–1.08)
Pattern				
Septal	84.3 (172)	81.2 (13)	0.72	0.81 (0.22–2.99)
Apical	7.4 (15)	12.5 (2)	0.36	1.80 (0.37–8.67)
Concentric	8.3 (17)	6.2 (1)	1.00	0.73 (0.09–5.90)
CMR parameter				
LVEF, %	71.0 (64.8–76.9)	68.0 (51.2–75.2)	<0.05	0.95 (0.92–0.99)
Maximal wall thickness, mm	19.0 (16.0–22.5)	20.0 (17.5–24.5)	0.35	1.05 (0.95–1.16)
LV mass, g	154.8 (126.8–190.9)	186.0 (150.3–229.7)	0.05	1.01 (1.00–1.01)
LV mass index, g/m^2	81.4 (66.2–95.3)	97.1 (82.0–126.0)	<0.01	1.02 (1.00–1.03)
LVOT obstruction, %	30.9 (63.0)	37.5 (6.0)	0.58	1.34 (0.47–3.86)
LGE	65.2 (133.0)	93.8 (15.0)	<0.05	8.01 (1.04–61.9)
LGE, g	1.8 (0.0–7.4)	15.6 (5.9–23.4)	<0.001	1.02 (1.00–1.04)
LGE, % LV	1.1 (0.0–4.6)	7.4 (3.4–17.3)	<0.001	1.05 (1.01–1.09)
Surface area LGE, mm^2	75.6 (0.0–272.3)	393.1 (185.7–849.9)	<0.001	1.00 (1.00–1.00)
Surface area/LV mass, mm^2/g	0.5 (0.0–1.7)	2.0 (1.3–4.8)	<0.001	1.20 (1.05–1.38)
SCD risk factors				
Maximal wall thickness >30 mm	3.4 (7.0)	6.3 (1.0)	0.46	1.88 (0.22–16.27)
History of spontaneous VT	4.9 (10.0)	12.5 (2.0)	0.21	2.77 (0.55–13.90)
Family history of SCD	4.4 (9.0)	6.3 (1.0)	0.54	1.44 (0.17–12.18)
Unexplained syncope	4.9 (10.0)	12.5 (2.0)	0.21	2.77 (0.55–13.90)
LVOT obstruction >30 mm Hg	12.2 (22.0)	13.3 (2.0)	1.00	1.10 (0.23–5.23)
Number of SCD risk factors				
0	76.5 (156.0)	68.8 (11.0)	0.54	0.68 (0.22–2.04)
1	19.6 (40.0)	18.8 (3.0)	1.00	0.95 (0.26–3.48)
2	2.9 (6.0)	6.3 (1.0)	0.38	2.20 (0.25–19.48)

Centro Cardiologico
Monzino

① Hypertrophic cardiomyopathy
Differential diagnosis

Amiloidosis

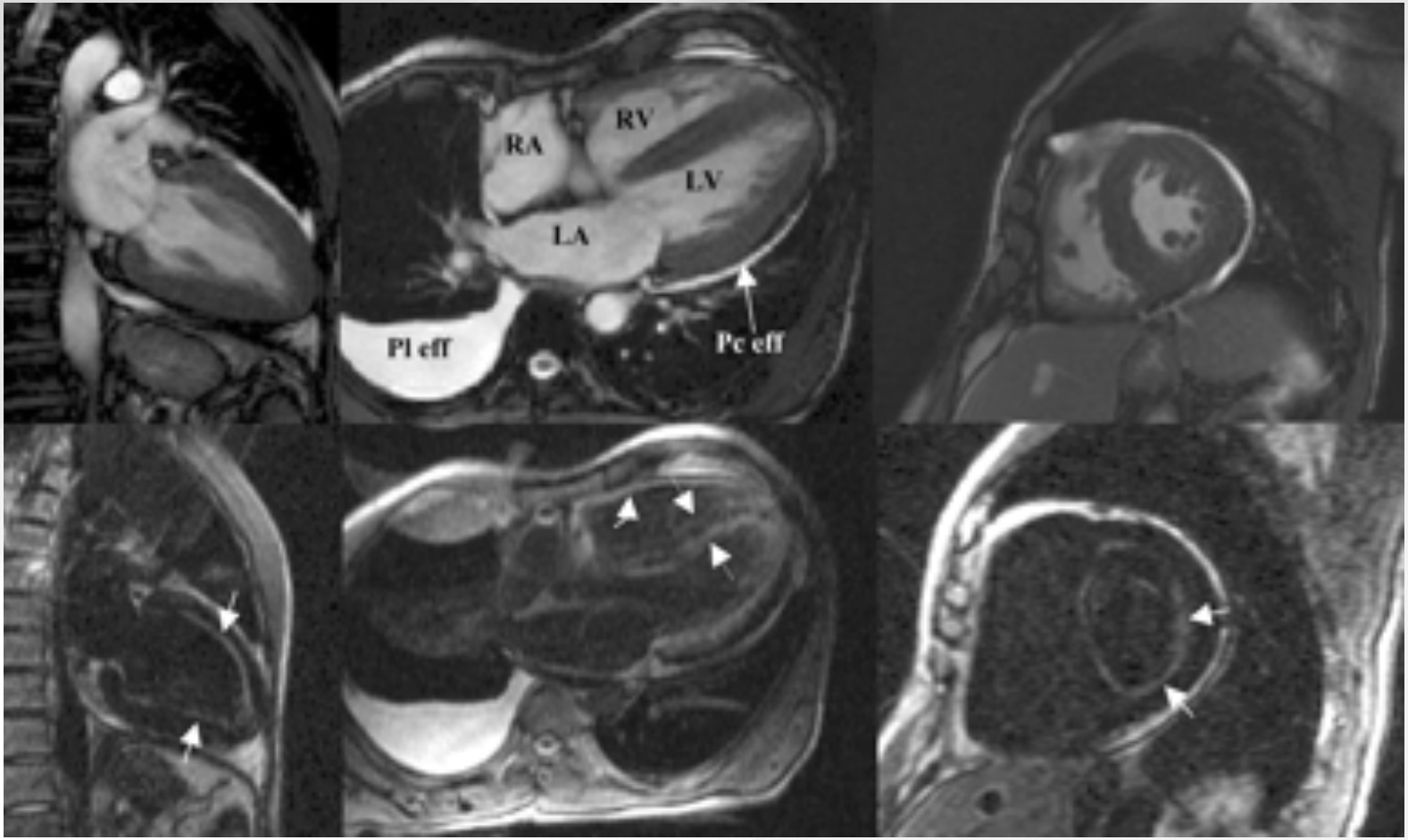

Centro Cardiologico
Monzino

① Hypertrophic cardiomyopathy
Differential diagnosis

Fabry Disease

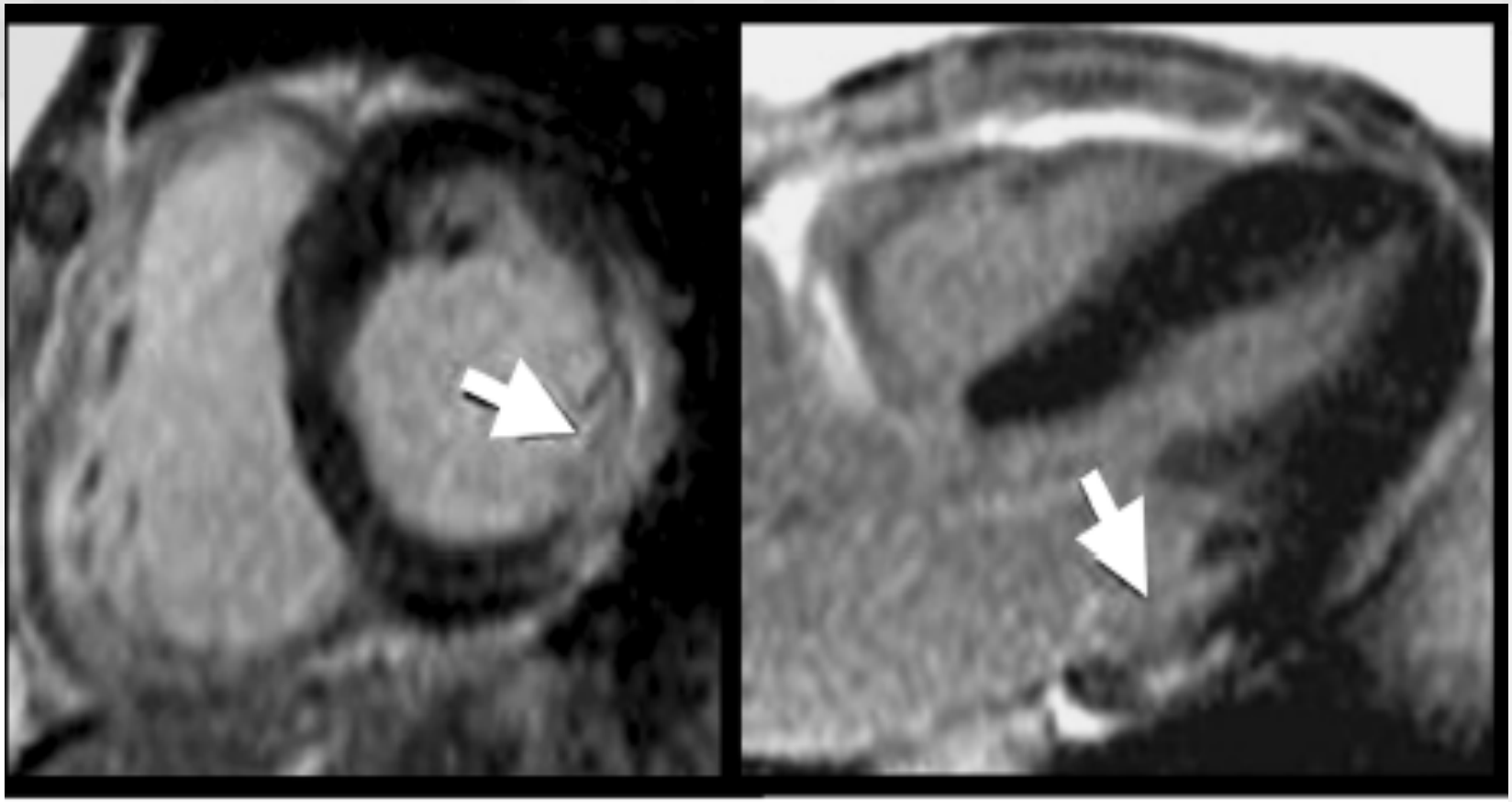

② Dilated cardiomyopathy

- La prognosi varia in relazione all'eziologia; in media la mortalità ad 1 anno è pari al 10-20%.

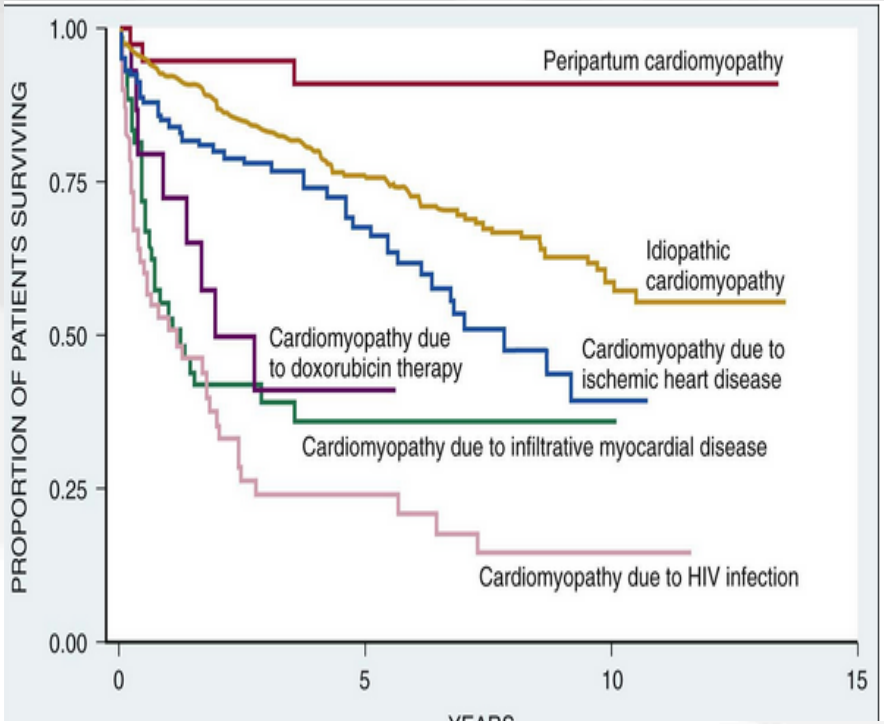

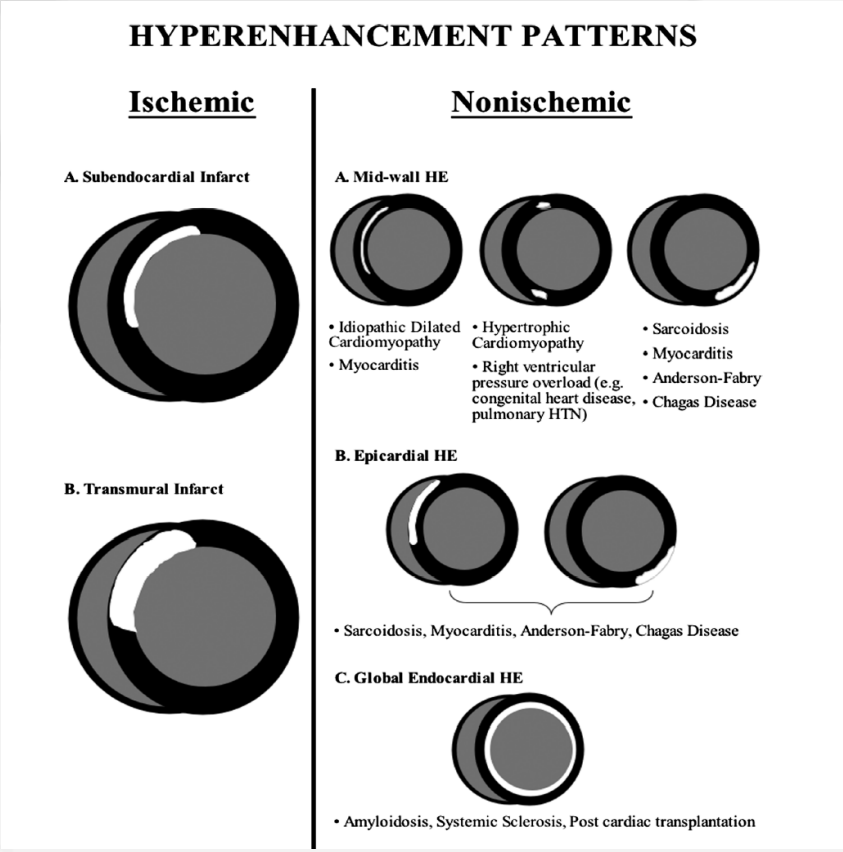

② Dilated cardiomyopathy

Differentiation of Heart Failure Related to Dilated Cardiomyopathy and Coronary Artery Disease Using Gadolinium-Enhanced Cardiovascular Magnetic Resonance

J.A. McCrohon, FRACP, PhD; J.C.C. Moon, MB, BS, MRCP;
S.K. Prasad, MD, MRCP; W.J. McKenna, MD, FRCP, FESC; C.H. Lorenz, PhD;
A.J.S. Coats, DM, FRCP, FESC; D.J. Pennell, MD, FRCP, FESC

Circ 2003

Diagnostic targets for CMR in DCM include progressive LV dilation, LV systolic dysfunction, and regional midwall myocardial fibrosis.

CAD

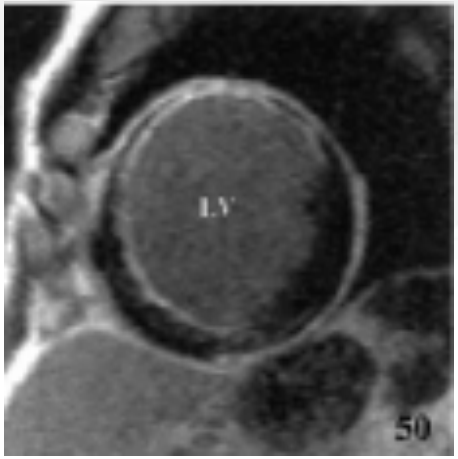

No CAD

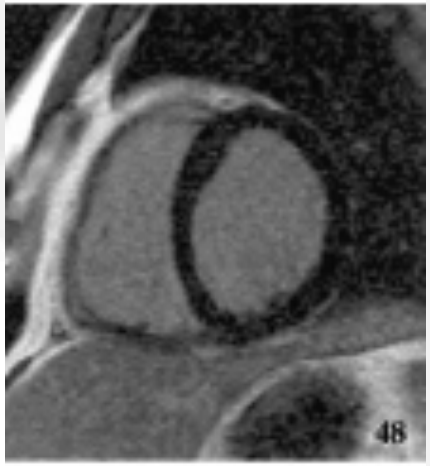

No CAD

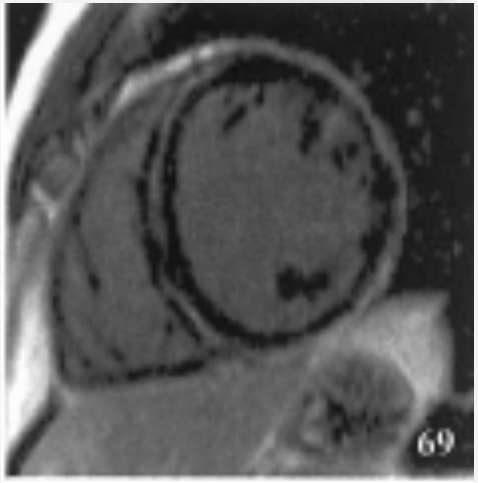

Role of Cardiovascular Magnetic Resonance as a Gatekeeper to Invasive Coronary Angiography in Patients Presenting With Heart Failure of Unknown Etiology

Ravi G. Assomull, MRCP; Carl Shakespeare, MD, FRCP; Paul R. Kalra, MA, FRCP; Guy Lloyd, MD, FRCP; Ankur Gulati, MRCP; Julian Strange, MRCP; William M. Bradlow, MD, MRCP; Jonathan Lyne, MRCP; Jennifer Keegan, PhD; Philip Poole-Wilson, FRCP, FESC; Martin R. Cowie, MD, FRCP; Dudley J. Pennell, MD, FRCP, FESC; Sanjay K. Prasad, MD, FRCP, FESC

	LGE-CMR (95% Confidence Interval), %	CA (95% Confidence Interval), %
Sensitivity	100 (88–100)	93 (77–99)
Specificity	96 (89–99)	96 (89–99)
PPV	88 (72–97)	87 (70–96)
NPV	100 (96–100)	98 (92–100)
Diagnostic accuracy	97	95

Centro Cardiologico
Monzino

Circulation 2011

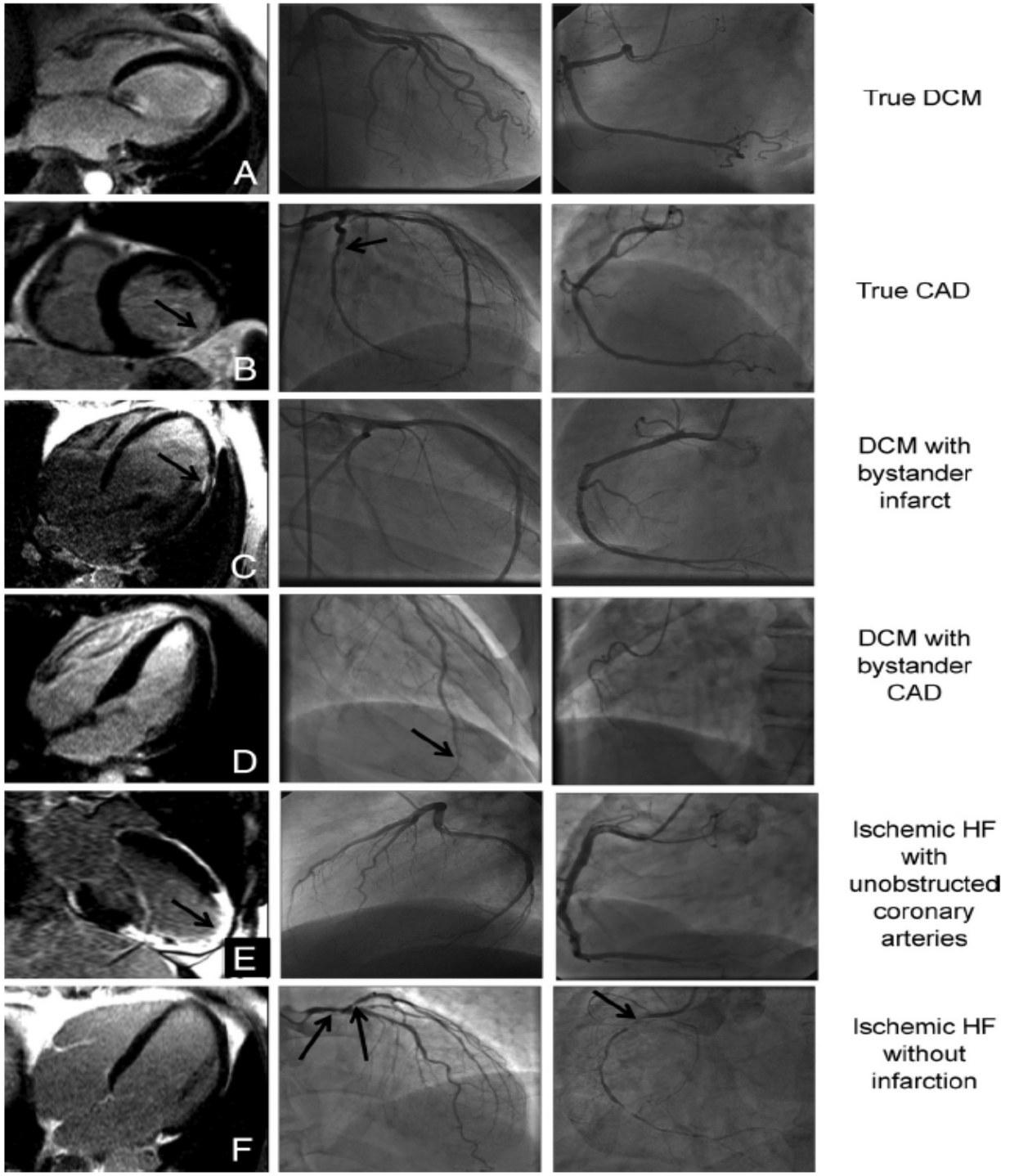

Figure 2. Late gadolinium-enhanced cardiovascular magnetic resonance (LGE-CMR) and associated coronary angiogram (CA) images of diagnosis subtypes. Six different diagnoses are graphically represented with LGE-CMR images followed by CA images of the left coronary artery and right coronary artery. **A,** True dilated cardiomyopathy (DCM) shows an LGE-CMR image with no subendocardial LGE and unobstructed coronary arteries on CA. **B,** True coronary artery disease (CAD) with a circumflex territory infarct on CMR (arrows) and a severe proximal circumflex artery stenosis (arrows). **C,** A small area of subendocardial LGE (arrows) is seen in a severely dilated left ventricle with severe global systolic impairment and unobstructed coronary arteries representing DCM with bystander infarct. **D,** Distal disease of the left anterior descending artery (arrows) with no evidence of subendocardial LGE (DCM with bystander CAD). **E,** A large apical infarct is seen on LGE-CMR in the context of unobstructed coronary arteries suggesting ischemic heart failure (HF) with unobstructed coronary arteries. **F,** A possible scenario of ischemic heart failure without infarction. There is no LGE on CMR but there is severe proximal 3-vessel disease, including left main stem disease, on CA (arrows). No patient in our study had this scenario; therefore, the images are for illustration only.

② Dilated cardiomyopathy

Journal of the American College of Cardiology
© 2006 by the American College of Cardiology Foundation
Published by Elsevier Inc.

Vol. 48, No. 10, 2006
ISSN 0735-1097/06/$32.00
doi:10.1016/j.jacc.2006.07.049

FOCUS ISSUE: CARDIAC IMAGING

Cardiovascular Magnetic Resonance, Fibrosis, and Prognosis in Dilated Cardiomyopathy

Ravi G. Assomull, MRCP,*† Sanjay K. Prasad, MD, MRCP,*† Jonathan Lyne, MRCP,* Gillian Smith, MSc,* Elizabeth D. Burman, MSc,* Mohammed Khan, MSc, MPH,‡ Mary N. Sheppard, MD, FRCPath,§ Philip A. Poole-Wilson, MD, FRCP,† Dudley J. Pennell, MD, FRCP, FESC, FACC*†

London, United Kingdom

The presence of fibrosis identified with LGE has been found to be associated with adverse cardiac events.

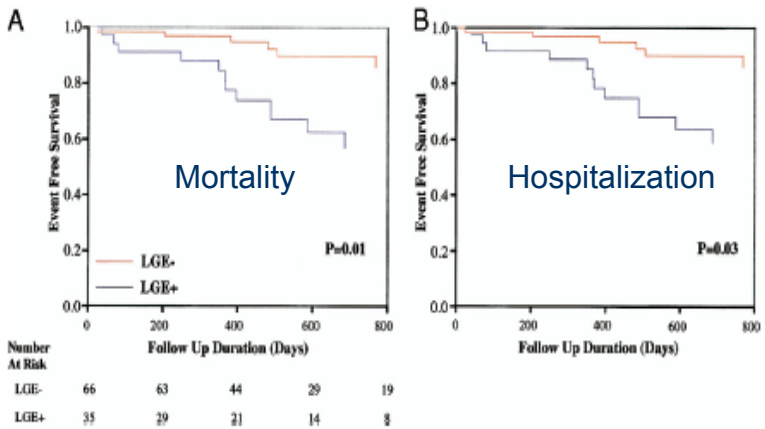

Figure 3. (A) Kaplan-Meier survival estimates for the primary end point of all-cause mortality or hospitalization due to cardiovascular causes. (B) Same data adjusted for baseline differences in age, left ventricular (LV) end-systolic volume, LV end-diastolic volume, LV ejection fraction, right ventricular ejection fraction, and treatment with digoxin. LGE+ = patients with late gadolinium enhancement; LGE− = patients without late gadolinium enhancement.

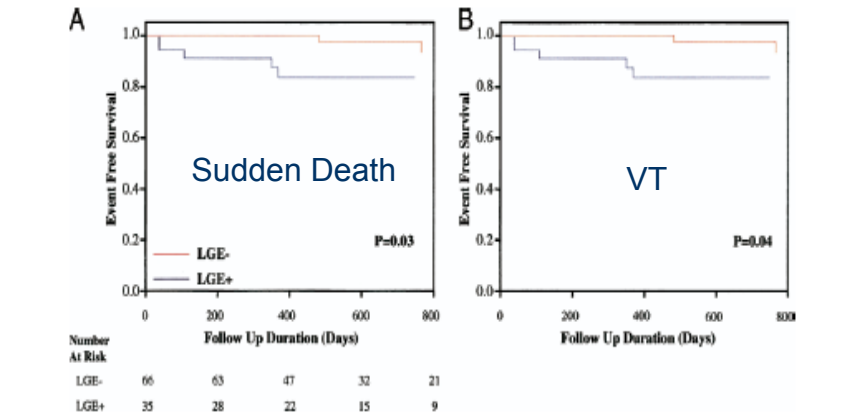

Figure 4. (A) Kaplan-Meier survival estimates for the secondary end point of sudden cardiac death or sustained ventricular tachycardia. (B) Same data adjusted for baseline differences in left ventricular ejection fraction. LGE+ = patients with late gadolinium enhancement; LGE− = patients without late gadolinium enhancement.

Centro Cardiologico
Monzino

Circulation
Heart Failure

The Incremental Prognostic Value of Myocardial Fibrosis in Patients With Non-Ischemic Cardiomyopathy Without Congestive Heart Failure

Pier Giorgio Masci, Constantinos Doulaptsis, Erika Bertella, Alberico Del Torto, Rolf Symons, Gianluca Pontone, Andrea Barison, Walter Droogné, Daniele Andreini, Valentina Lorenzoni, Paola Gripari, Saima Mushtaq, Michele Emdin, Jan Bogaert and Massimo Lombardi

Outcome	Overall (n=228)	Patients with LGE, (n=61)	Patients without LGE, (n=167)	Hazard Ratio (95% CI)	P-Value
Combined end-point n, (%)	49(21)	31(51)	18(11)	5.104(2.783-9.361)	<0.001
Cardiovascular deaths	4(2)	1 (2)	3(2)	1.241(0.110-13.941)	0.861
CHF	37(16)	24(39)	13(8)	5.234(2.609-10.500)	<0.001
Aborted SCD	8(4)	6(10)	2(1)	8.314(1.664-41.548)	0.010

Hazard Ratio is calculated for patients with LGE versus those without LGE. P-Values are obtained from Univariate Cox proportional hazard models. CHF: congestive heart

Conclusions—In NICM patients without history of CHF, myocardial fibrosis is a strong and independent predictor of outcome providing incremental prognostic information and improvement in risk stratification beyond clinical data and degree of LV dysfunction.

② Dilated cardiomyopathy

Magnetic Resonance Assessment of the Substrate for Inducible Ventricular Tachycardia in Nonischemic Cardiomyopathy

Saman Nazarian, MD; David A. Bluemke, MD, PhD; Albert C. Lardo, PhD; Menekhem M. Zviman, PhD; Stanley P. Watkins, MD, MPH; Timm L. Dickfeld, MD, PhD; Glenn R. Meininger, MD; Ariel Roguin, MD, PhD; Hugh Calkins, MD; Gordon F. Tomaselli, MD; Robert G. Weiss, MD; Ronald D. Berger, MD, PhD; João A.C. Lima, MD; Henry R. Halperin, MD, MA

Recently, focal septal fibrosis in DCM, the so-called “midwall sign,” has been linked to ventricular arrhythmia

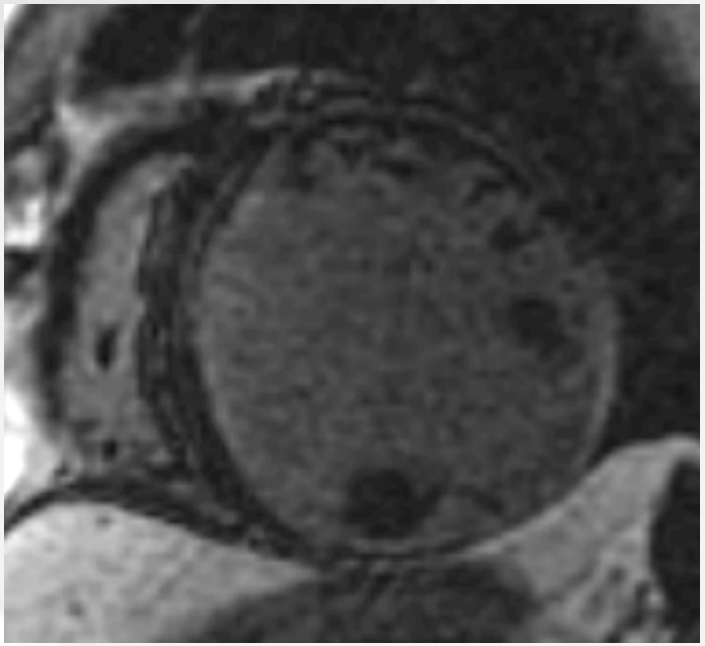

③ Left Ventricle non compacttion

Journal of the American College of Cardiology
© 2005 by the American College of Cardiology Foundation
Published by Elsevier Inc.
Vol. 46, No. 1, 2005
ISSN 0735-1097/05/$30.00
doi:10.1016/j.jacc.2005.03.045

Clinical Insights From Cardiac Imaging

Left Ventricular Non-Compaction

Insights From Cardiovascular Magne

Steffen E. Petersen, MD,*† Joseph B. Selvanay
Matthew D. Robson, PHD,*† Jane M. Francis,
Hugh Watkins, MD, PHD, FRCP,† Stefan Ne
Oxford and London, United Kingdom

① An end-diastolic to compacted LV m an or equal to 2.3 d

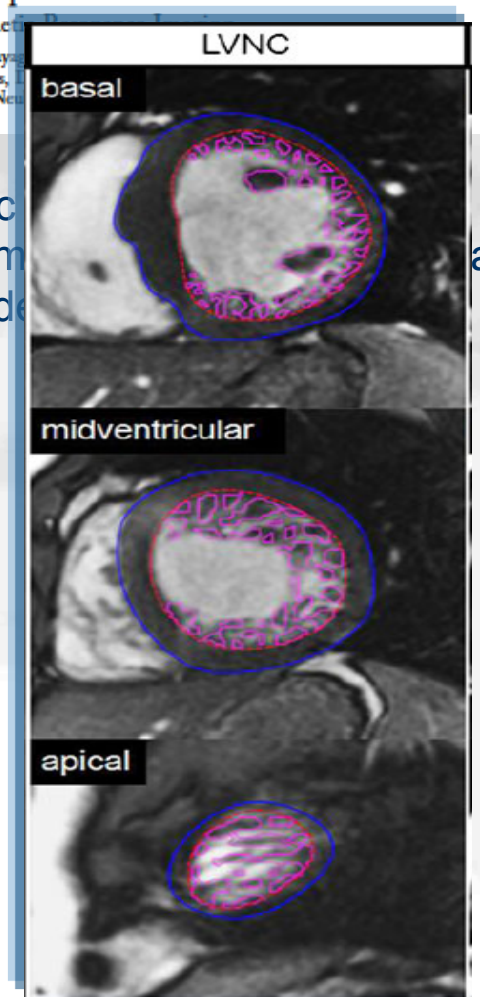

Our study provides redefined and extended CMR criteria for diagnosing and discriminating LVNC from other cardio-myopathies. These four basic criteria are (Table 4)

1. Percentage LV-$MM_{non\text{-}compacted}$ >25 %
2. Total LV-$MMI_{non\text{-}compacted}$ >15 g/m^2
3. Non-compacted/compacted myocardium ratio of ≥3:1 in at least one of the other segments (1–3, 7–16) excluding the apical segment 17
4. Trabeculation in segments 4–6≥2:1 (non-compacted/compacted)

Centro Cardiologico Monzino

④ ARVD

- It 'a disease that is characterized by the presence of fibro-adipose alteration borne infarction associated with increased incidence of arrhythmic events.
- It 'a family pathology in 50% of cases and has an autosomal dominant with variable penetrance.
- The prevalence in the general population is 1 in 1,000 and 1 in 5000

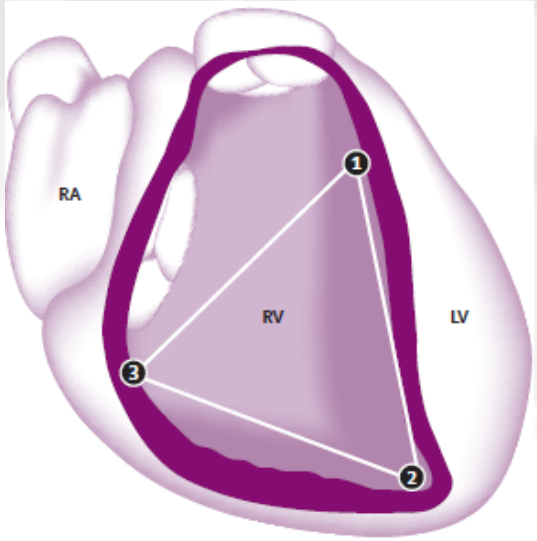

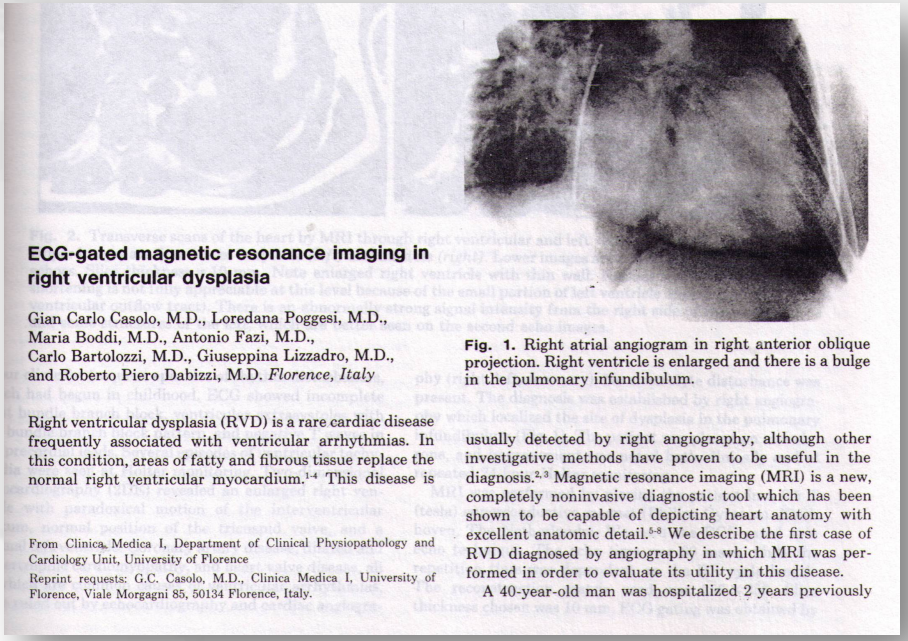

ECG-gated magnetic resonance imaging in right ventricular dysplasia

Gian Carlo Casolo, M.D., Loredana Poggesi, M.D., Maria Boddi, M.D., Antonio Fazi, M.D., Carlo Bartolozzi, M.D., Giuseppina Lizzadro, M.D., and Roberto Piero Dabizzi, M.D. *Florence, Italy*

Right ventricular dysplasia (RVD) is a rare cardiac disease frequently associated with ventricular arrhythmias. In this condition, areas of fatty and fibrous tissue replace the normal right ventricular myocardium.[1-4] This disease is usually detected by right angiography, although other investigative methods have proven to be useful in the diagnosis.[2,3] Magnetic resonance imaging (MRI) is a new, completely noninvasive diagnostic tool which has been shown to be capable of depicting heart anatomy with excellent anatomic detail.[5-8] We describe the first case of RVD diagnosed by angiography in which MRI was performed in order to evaluate its utility in this disease.

A 40-year-old man was hospitalized 2 years previously

Fig. 1. Right atrial angiogram in right anterior oblique projection. Right ventricle is enlarged and there is a bulge in the pulmonary infundibulum.

From Clinica Medica I, Department of Clinical Physiopathology and Cardiology Unit, University of Florence

Reprint requests: G.C. Casolo, M.D., Clinica Medica I, University of Florence, Viale Morgagni 85, 50134 Florence, Italy.

Centro Cardiologico Monzino

Lancet 2009; 373: 1289–1300

④ ARVD

- ❑ Often not visible
- ❑ The microscopic is "invisible“
- ❑ Can be nonspecific
- ❑ It can be noted in subjects "healthy“
- ❑ It shows good only in the most severe forms of ARVC

Etc ..

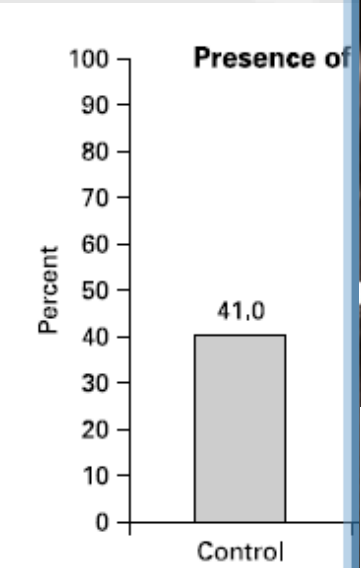

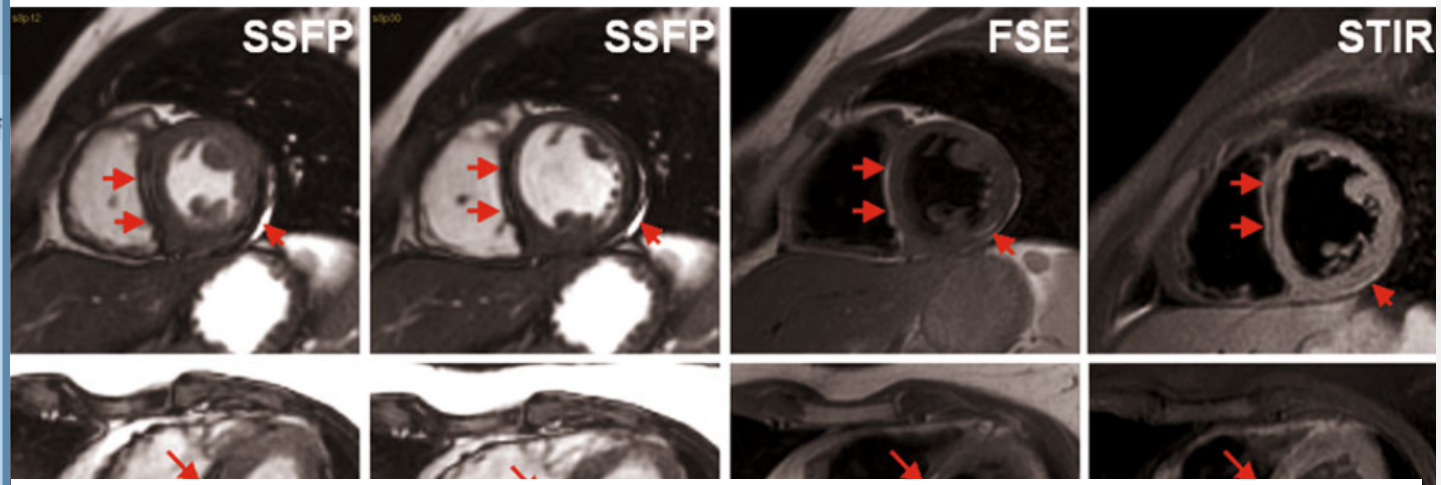

- SSFP had 100% sensitivity and 98.8% of specificity to detect LV intramyocardial fat in ARVC and in ischemic heart disease.

Centro Cardiologico Monzino

Bluemke DA Cardiology 2003

④ ARVD

	Original	Revised
Major	• Severe dilatation and reduction of RV ejection fraction with no (or mild) LV impairment • Localized RV aneurysm (akinetic or dyskinetic areas with diastolic bulging) • Severe Segmental dilatation of the RV	By 2D Echo • Regional RV akinesia, dyskinesia or aneurysm • And 1 of the following (end diastole): ○ PLAX RVOT ≥32mm ○ PSAX RVOT ≥36mm ○ Or fractional area change ≤33% By MRI • Regional RV akinesia, dyskinesia or aneurysm or dyssynchronous RV contraction • And one of the following: ○ Ratio of RV end-diastolic volume to BSA ≥110 mL/m^2 (male) or ≥100 mL/m^2 (female) ○ Or RV ejection fraction ≤40% By RV angiography: • Regional RV akinesia, dyskinesia or aneurysm
Minor	• Mild global RV dilatation and/or ejection fraction with normal LV • Mild segmental dilatation of the RV • Regional RV hypokinesia	By 2D Echo: • Regional RV akinesia, dyskinesia • And 1 of the following: ○ PLAX RVOT ≥29 to <32mm ○ PSAX RVOT ≥32 to <36mm ○ Or fractional area change >33% to ≤40% By MRI: • Regional RV akinesia, dyskinesia or aneurysm or dyssynchronous RV contraction • And one of the following: ○ Ratio of RV end-diastolic volume to BSA ≥100 to <110 mL/m^2 (male) or ≥90 to <100 mL/m^2 (female) ○ Or RV ejection fraction >40% to ≤45%

Centro Cardiologico Monzino

Circulation. 2010;121:1533-1541

④ ARVD

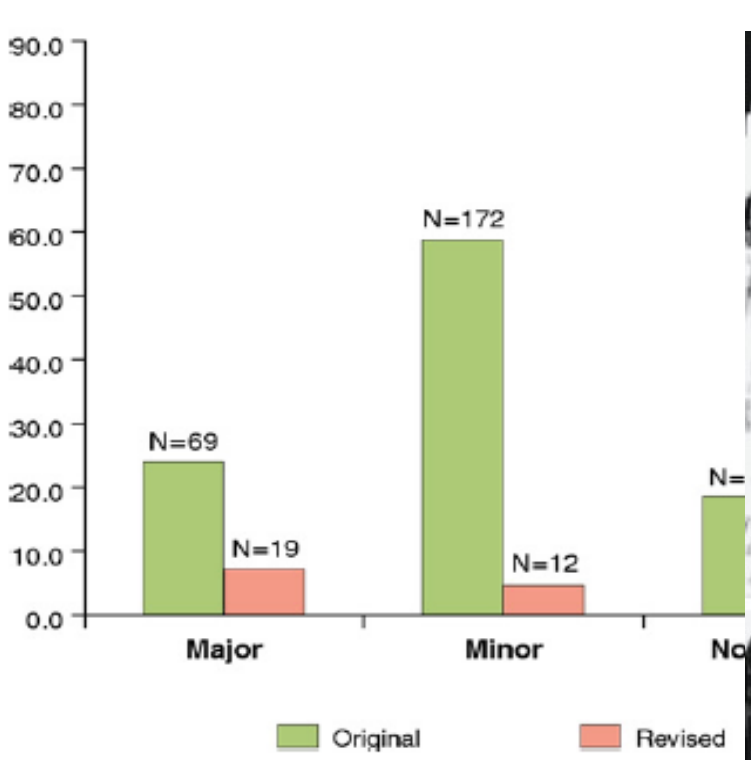

Figure 2. Proportional Incidence of Original and Revise

The graph shows the different incidence of patients with n
minor criteria, or without criteria according to the original
resonance criteria (**green bars**) and the revised criteria (ora

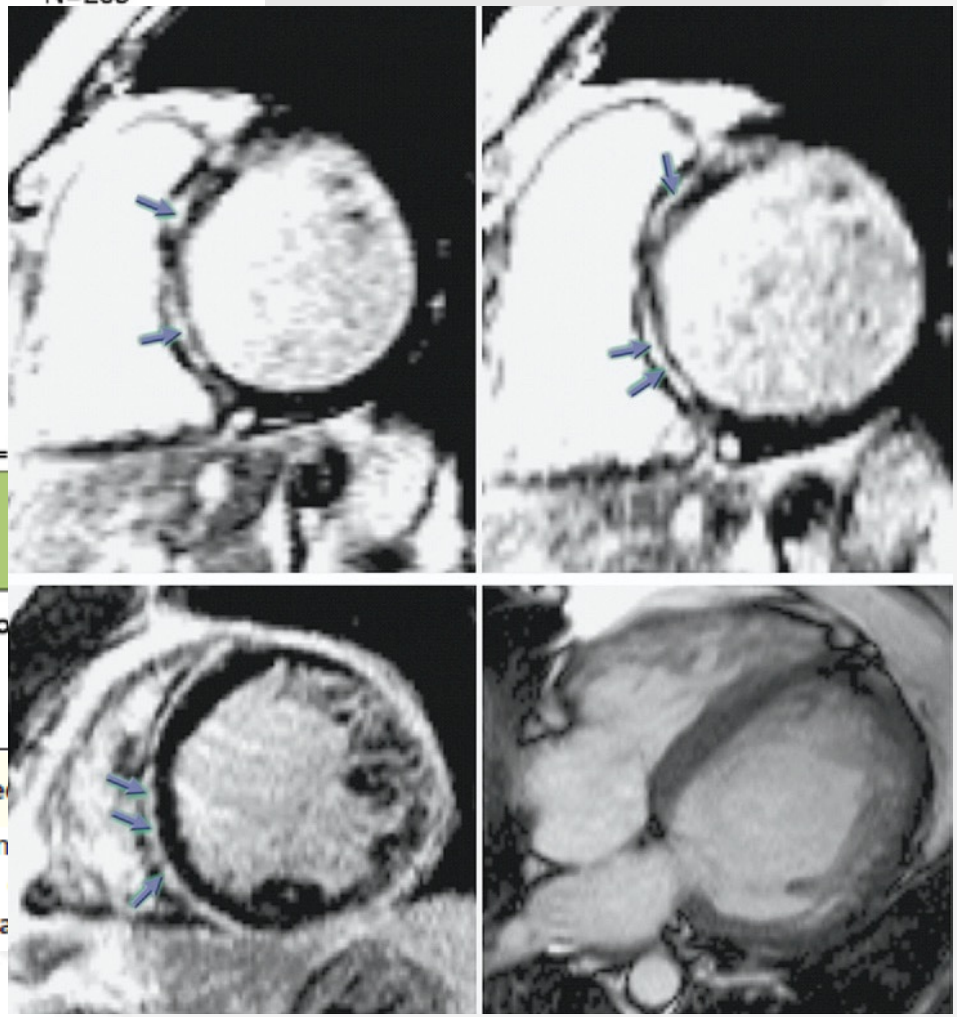

TAKE HOME MESSAGE

FIRST DIAGNOSIS

① To rule out the ischemic etiology avoding invasive coronary angiography

② … Once the ischemic etiology has been excluded to classify the patient in the right CMP

③ In the subset of CMP with increased left ventricle mass to provide differential diagnosis between physiological hypertrophy, HCM and infiltrative disease

④ To better stratify the patients beyond the standard parameters

FOLLOW-UP

① To evaluate therapeutic treatment benefit

② Before invasive decision ….. ICD implantation ?

THANKS

www.cardiologicomonzino.it

Gianluca.pontone@ccfm.it

Director of Cardiology
Prof. Cesare Fiorentini, MD

Area of Cardiovascular Imaging
Dr. Mauro Pepi, MD

Cardiovascular MR Unit
Gianluca Pontone, MD, PhD

Radiology Unit
Enrica Nobili, MD

Cardiovascular CT Unit
Daniele Andreini, MD, PhD

Cardiologist
Paola Gripari, MD
Saima Mushtaq. MD
Marco Guglielmo, MD

Radiologist
Andrea Annoni, MD
Alberto Formenti, MD
Maria Petulla', MD

Fellows
Anna Solbiati, MD
Crsitina Rota, MD
Chiara Segurini, MD
Andrea Baggiano, MD
Edoardo Conte, MD
Virginia Beltrama, MD

Centro Cardiologico Monzino
Department SCCO - Cardiovascular Section
Università degli Studi di Milano
Hands on Cardiac CT
Training course
january/december 2015

Centro Cardiologico Monzino
Department SCCO - Cardiovascular Section
Università degli Studi di Milano
Hands on Cardiac Magnetic Resonance
january/december 2015

EACVI
EUROPEAN ASSOCIATION OF CARDIOVASCULAR IMAGING
A Registered Branch of the ESC

EUROPEAN SOCIETY OF CARDIOLOGY®

ESCR
European Society of Cardiac Radiology

SOCIETY OF CARDIOVASCULAR COMPUTED TOMOGRAPHY

SCMR
Society for Cardiovascular Magnetic Resonance

Centro Cardiologico Monzino

THANKS

www.cardiologicomonzino.it
Gianluca.pontone@ccfm.it

Director of Cardiology
Prof. Cesare Fiorentini, MD

Area of Cardiovascular Imaging
Dr. Mauro Pepi, MD

Cardiovascular MR Unit
Gianluca Pontone, MD, PhD

Radiology Unit
Enrica Nobili, MD

Cardiovascular CT Unit
Daniele Andreini, MD, PhD

Cardiologist
Paola Gripari, MD
Saima Mushtaq. MD
Marco Guglielmo, MD

Radiologist
Andrea Annoni, MD
Alberto Formenti, MD
Maria Petulla', MD

Fellows
Anna Solbiati, MD
Crsitina Rota, MD
Chiara Segurini, MD
Andrea Baggiano, MD
Edoardo Conte, MD
Virginia Beltrama, MD

Centro Cardiologico
Monzino

THANKS

www.cardiologicomonzino.it
Gianluca.pontone@ccfm.it

Director of Cardiology
Prof. Cesare Fiorentini, MD

Area of Cardiovascular Imaging
Dr. Mauro Pepi, MD

Cardiovascular MR Unit
Gianluca Pontone, MD, PhD

Radiology Unit
Enrica Nobili, MD

Cardiovascular CT Unit
Daniele Andreini, MD, PhD

Cardiologist
Paola Gripari, MD
Saima Mushtaq. MD
Marco Guglielmo, MD

Radiologist
Andrea Annoni, MD
Alberto Formenti, MD
Maria Petulla', MD

Fellows
Anna Solbiati, MD
Crsitina Rota, MD
Chiara Segurini, MD
Andrea Baggiano, MD
Edoardo Conte, MD
Virginia Beltrama, MD

EURECA *Imaging* ITALY

EUropean **RE**gistry on **CA**rdiac *Imaging*
for the Detection and Characterization of Stable Coronary Artery Disease
ITALY

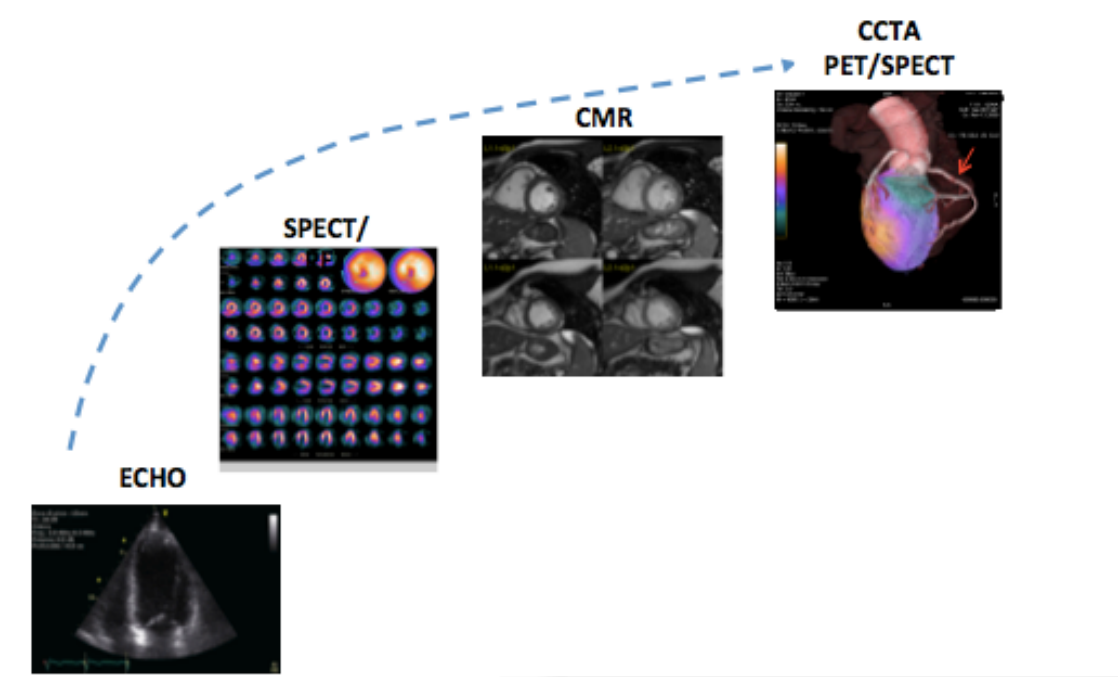

Centro Cardiologico
Monzino